

学位論文

Immunohistochemical Expression of Heat Shock
Proteins in the Mouse Periodontal Tissues due to
Orthodontic Mechanical Stress

(歯科矯正学的メカニカルストレスによるマウス歯根膜組織
における HSPs の免疫組織化学的発現)

村岡 理奈

大学院歯学独立研究科 硬組織疾患制御再建学講座
(主指導教員: 川上 敏行 教授)

松本歯科大学大学院歯学独立研究科博士(歯学)学位申請論文

Immunohistochemical Expression of Heat Shock Proteins in
the Mouse Periodontal Tissues due to Orthodontic
Mechanical Stress

Rina Muraoka

Department of Hard Tissue Research, Graduate School of Oral Medicine
(Chief Academic Advisor : Professor Toshiyuki Kawakami)

The thesis submitted to the Graduate School of Oral Medicine,
Matsumoto Dental University, for the degree Ph.D. (in Dentistry)

要旨

歯科矯正治療において、矯正装置によるメカニカルストレスは歯周組織に作用し、歯根膜組織に改変現象が起こる。その結果として“歯の移動”が起こる。すなわち、歯根膜組織に作用しているメカニカルストレスを軽減させるような組織反応が生じる結果として歯は“移動”するのである。これは歯根膜の恒常性維持による反応と考えることができる。近年、歯周組織はメカニカルストレスや炎症に反応し種々の分子を発現して活発なリモデリングを引き起こしている事が明らかとなってきた。以前より、熱ショックや細胞傷害性刺激、メカニカルストレスの負荷により発現するタンパクとして、Heat Shock Proteins (HSPs)が知られている。しかし、実験的歯の移動に伴う歯根膜組織での動態やその役割については、傷害性刺激に対する調節的な細胞反応と同様にこれまで追究されていない。そこで本研究では、歯周組織に歯科矯正学的メカニカルストレスを負荷することによって起こる歯根膜細胞の変化について、マウスを用いて歯の移動実験を行い、病理組織学的に追究するとともに、同時に発現しているであろう HSP27 と p-HSP27 の初期における発現状況の変化について免疫組織化学的に検討した。

実験動物として8週齢の ddY 雄性マウスを使用し、Waldo 法によりマウスの上顎臼歯間にセパレーターを挿入して歯科矯正学的なメカニカルストレスの負荷を行った。実験開始後、経時的に当該部マウス上顎臼歯部歯周組織を摘出し、4%パラホルムアルデヒド 0.05Mリン酸緩衝固定液にて固定した。その後、EDTA 溶液にて脱灰を行った後、厚さ 5 μ m のパラフィン連続切片標本を作製し、病理組織学的に検討するとともに免疫組織化学的に HSP27 および p-HSP27 の発現状況を検討した。

その結果、メカニカルストレスを負荷後、H-E 染色にて病理組織学的検討を行ったところ、対照群の病理組織像との比較において、実験群では、メカニカルストレス負荷後の初期変化は 20 分群で起こり、歯根の相対移動は 3 時間群において最大になった。圧迫側では歯根膜腔はより狭くなり、歯根膜を構成する線維芽細胞の退行性変化が著しく認められ、エオシン好染性を増していた。最終的に強く圧迫された歯根膜線維芽細胞の核は核崩壊を起こしていた。

次に免疫組織化学的検討において、HSP27が種々のりん酸化酵素の作用によってりん酸化される過程を経て p-HSP27 として機能することから、同時に p-HSP27 の発現状況の変化を観察した。まず、対照群の歯根膜線維芽細胞はその全周にわたって HSP27 の活性がみられ、これは低い状態で保たれていた。p-HSP27 の活性はそれよりもかなり低い状態で保たれていた。これは HSP27、p-HSP27 は平常時においても弱発現し、歯根膜組織のホメオスタシスの維持や歯根膜線維芽細胞の活性化による組織の修復に密接に関与しているためだと考えられる。また、実験群では、HSP27 は 10 分で牽引側の歯根膜線維芽細胞に免疫陽性反応の局在化がみられ、時間の経過とともにこれらの陽性反応は増強し、9 時間では歯根膜線維芽細胞、骨芽細胞にも強く発現していた。p-HSP27 も経時的に陽性反応の増強を示したが、HSP27 の発現を追うように、若干遅れていた。また、この時期の牽引側歯根膜組織には Runx2 などの骨芽細胞の活性化を誘導する因子の発現があり、HSP27 は、骨添加傾向への分子シャペロンとして働いている可能性が強いと考えられる。

以上、これらの実験結果は歯根膜組織に対するメカニカルストレスにより誘導されたものと考えられ、HSP27 がそのりん酸化した p-HSP27 として牽引側歯根膜線維芽細胞の活性化によるホメオスタシスの維持や、また骨芽細胞活性化による同部への骨添加傾向へのシャペロンとして働いていることを強く示唆した。

IMMUNOHISTOCHEMICAL EXPRESSION OF HEAT SHOCK PROTEINS IN THE MOUSE PERIODONTAL TISSUES DUE TO ORTHODONTIC MECHANICAL STRESS*

R. Muraoka^{1,2}, K. Nakano^{1,3}, S. Kurihara³, K. Yamada^{2,4}, T. Kawakami^{1,3}

¹Hard Tissue Pathology Unit, Matsumoto Dental University Graduate School of Oral Medicine, Shiojiri, Japan

²Department of Orthodontics, Matsumoto Dental University School of Dentistry, Shiojiri, Japan

³Matsumoto Dental University Institute for Oral Science, Shiojiri, Japan

⁴Clinical Evaluation Unit, Matsumoto Dental University Graduate School of Oral Medicine, Shiojiri, Japan

Abstract

The histopathology of periodontal ligament of the mouse subjected to mechanical stress was studied. Immunohistochemical expressions of HSP27 and p-HSP27 were examined. Experimental animals using the maxillary molars of ddY mouse by Waldo method were used in the study. A separator was inserted to induce mechanical stress. After 10 minutes, 20 minutes, 1 hour, 3 hours, 9 hours and 24 hours, the regional tissues were extracted, fixed in 4% paraformaldehyde and 0.05M phosphate-buffered fixative solution. Paraffin sections were made for immunohistochemistry using HSP27 and p-HSP27. In the control group, the periodontal ligament fibroblasts expressed low HSP27 and p-HSP27. However, in the experimental group, periodontal ligament fibroblasts expressed HSP27 10 minutes after mechanical load application in the tension side. The strongest expression was detected 9 hours after inducing mechanical load. p-HSP27 was also expressed in a time-dependent manner though weaker than HSP27. The findings suggest that HSP27 and p-HSP27 were expressed for the maintenance of homeostasis of periodontal ligament by the activation of periodontal ligament fibroblasts on the tension side. It also suggests that these proteins act as molecular chaperones for osteoblast activation and maintenance of homeostasis.

Key words: Heat shock protein, HSP27, periodontal ligament cells, mechanical stress, orthodontic tooth movement

INTRODUCTION

Orthodontic treatment results to mechanical stress inducing reorganization of periodontal ligament (PDL) collagen bundles. As a result, the periodontal tissues supporting the movement of the tooth called pressure side react with the appearance of osteoclasts responsi-

ble for bone resorption. On opposite side, generally known as tension side, activation of osteoblasts adds attachment to bone at the same time reorganization occurs in periodontal tissues. These actions would result to tooth movement. Mechanical stress transferred to the PDL causes tissue reaction causing tooth movement. This reaction of PDL is for the maintenance of homeostasis. In recent years, histological response and cellular differentiation, as well production of transcription factors regulating various morphogenetic phenomenon became more widely studied [1, 2]. It has become clear that maintaining homeostasis can lead to periodontal tissue remodeling and expression of active molecules in response to various mechanical stress and inflammation [3-8].

Traditionally, major proteins expressed in various tissues and organs due to mechanical load and stimulation of cytotoxic stress that is transiently expressed are known as heat shock proteins (HSPs) [9]. HSPs are not only induced by heat shock but also by various pathological changes such as ischemia, infection and inflammation; radiation, physical stress such as light, enzyme; heavy metal ions like arsenic, ethanol, free radicals, amino acid derivatives, various chemicals induced by stress [10, 11]. HSPs are thought to be involved in the regulation of cell function and defense as well as against injury to the cell [12-14]. However, its dynamic role in PDL and tooth movement as well as in the regulatory cell response against stimuli from experimental injury has not been investigated. Shigehara, et al. [15] studied the expressions of various mRNAs in the dental pulp after subjecting to mechanical stress during orthodontic movement but the expression of HSP was not mentioned. In our knowledge and in search of literatures, HPS expression in periodontal tissues is very limited. Maeda et al. [10] reported that cultured human PDL-derived fibroblast-like cells when subjected to continuous compression expressed HSP60, 70 and 90. Also, Okazaki et al. [11] reported the increased expression of HSP47, 60 and 70 by *in vitro* cyclic loading of stretching force in human PDL fibroblasts. Furthermore, Araujo et al. [16] mentioned that in culture experiment, microarray revealed that only HSP70 increased when human PDL fibroblasts were exposed to mechanical stress. HSP is classified into two types de-

*This study was conducted as thesis fulfillment for the PhD degree in Dentistry of Dr Rina Muraoka, under the supervision of Professor Toshiyuki Kawakami, Hard Tissue Pathology Unit, Department of Hard Tissue Research, Matsumoto Dental University Graduate School of Oral Medicine.

IMMUNOHISTOCHEMISTRY

Slides underwent deparaffinization and then subjected to pre-treatment for 30 minutes in incubator at 60°C. Immunohistochemistry was done with Dako Envision + Kit-K4006 (Dako, Glostrup, Denmark). Primary antibodies used were HSP27 mouse monoclonal antibody (HSP27 (SPM252): sc-65567, Santa Cruz Biotechnology, Inc., Santa Cruz, CA, USA, with a concentration of 1:5000) and mouse p-HSP27 rabbit polyclonal antibody (p-HSP27 (Ser 15): sc-101699, Santa Cruz Biotechnology, Inc., Santa Cruz, CA, USA, with a concentration of 1:5000). Specimens were counterstained with hematoxylin. For negative controls, specimens were stained without primary antibodies.

RESULTS

HISTOPATHOLOGICAL EXAMINATION

Control group

When distal buccal root of the upper first molar was horizontally examined, the alveolar bone socket was in oval shape with a long diameter of 550 µm and a short diameter of 450 µm though a small variation of size between the samples existed. The tooth root was located almost in the center of the alveolar socket. The mesial side has a slight deviation where the PDL space is about 50 µm. The distal PDL in between the alveolar bone and the distal buccal root of the left maxillary first molar were relatively arranged in order (Fig. 4, C-H, C-T). Spindle-shaped fibroblasts with oval nuclei can be seen along the PDL fibers. However, some sites also showed PDL fibroblasts positioned in a slightly different direction. Interspersed with the collagen bundles are capillaries filled with few erythrocytes. The root surface of acellular cementum is darkly stained with hematoxylin. The alveolar bone contains few flattened osteoblasts with oval nucleus.

In contrast, in the mesial PDL of the distal buccal root, the PDL fibroblasts were observed in a diagonal orientation (Fig. 4, C-P). Spindle-shaped PDL fibroblasts with oval nuclei were relatively even. The cementum and alveolar bone surfaces were the same as the distal segment.

Experimental group

PDL in the tension side

Changes in the distal buccal root of maxillary first molar were markedly different in the experimental group. The side near the separator (distal PDL of the distal buccal root of right maxillary first molar) is the tension side; the opposite side (mesial PDL of the distal buccal root of the maxillary first molar) is the pressure side.

In the 10 minutes group, the tooth moved slightly to the mesial. However, changes in the width of the PDL were not clear. The nucleus of PDL fibroblasts in the tension side was elongated. Their cytoplasm and nucleus were both slightly elongated.

In the 20 minutes group, difference between the tension and pressure side became apparent (Fig. 4, 20m-H). The PDL in the tension was arranged in a radial direction. The PDL fibroblasts have been strongly

stretched, spindle in shape and the nucleus is flattened or elliptical in shape. Also, congested capillaries are seen in the PDL (Fig. 4, 20m-T).

In the 1 hour group, the root moved further to the mesial direction (Fig. 4, 1h-H). The PDL width created a greater traction and the fibers had been stretched considerably. The nucleus was intensely stained with hematoxylin and became pyknotic. Destroyed collagen bundles in between gaps were observed. Nucleus disappeared in destroyed collagen bundles. The cells that have been stretched have wavy appearance. Some PDL fibroblasts with round nucleus were also observed. Congested capillaries in between collagen bundles increased. Osteoblasts lining the surface of alveolar bone are oval in shape (Fig. 4, 1h-T).

In the 3 hours group, the root continued to move mesially and the width of the PDL space increased (Fig. 4, 3h-H). The expected extension of PDL caused gaps in between fibers. The cytoplasm of spindle-shaped fibroblasts showed oval nuclei. The number of fibroblasts decreased compared to the 1 hour group. In particular, reduced chromatin condensation was observed in flattened cells. Congested capillaries are seen. Oval-shaped osteoblasts are observed lining the surface of the alveolar bone (Fig. 4, 3h-T).

In the 9 hours group, the root stopped moving in the mesial direction and the width of the PDL did not further increase and was maintained similar to the width observed in the 3 hours group. The gap in between collagen bundles was reduced. PDL fibroblasts are short, spindle in shape with oval nucleus. On the other hand, congested capillaries can still be observed.

In the 24 hours group, PDL cells are spindle in shape with thick oval nucleus. Osteoblasts lining the alveolar bone surface are oval or short cuboidal in shape. Dilated vessels and scattered hemorrhages can be observed (Fig. 4, 24h-H, 24h-T).

PDL in the pressure side

In the 10 minutes group, there were significant differences in the width in the tension and pressure sides of the PDL but showed little changes in cell morphology and arrangement of PDL fibroblasts. The nucleus was compressed and the intercellular space was reduced due to increased cell density.

In the 20 minutes group, the disorder in cell morphology of PDL fibroblasts became clearer in the pressure side. Nuclear form of PDL fibroblasts became further irregular, nuclear core became partly pyknotic. The osteoblasts have scanty cytoplasm, oval nuclei; some were flattened but the number of cells was lower compared to the 10 minutes group (Fig. 4, 20m-P).

In the 1 hour group, the PDL space is narrower; PDL fibroblasts are arranged in layers around the root. Moreover, the PDL cells showed various degenerative changes. The cytoplasm of PDL fibroblasts became eosinophilic, nucleus is flat, karyopyknosis was evident. Furthermore, osteoblasts lining the bone surface were reduced in number; the cytoplasm and nucleus became flattened by pressure and distinction among surrounding fibroblasts became difficult (Fig. 4, 1h-P).

In the 3 hours group, the PDL space further became narrower, degenerative changes were more severe that distinction of PDL cells was difficult. PDL

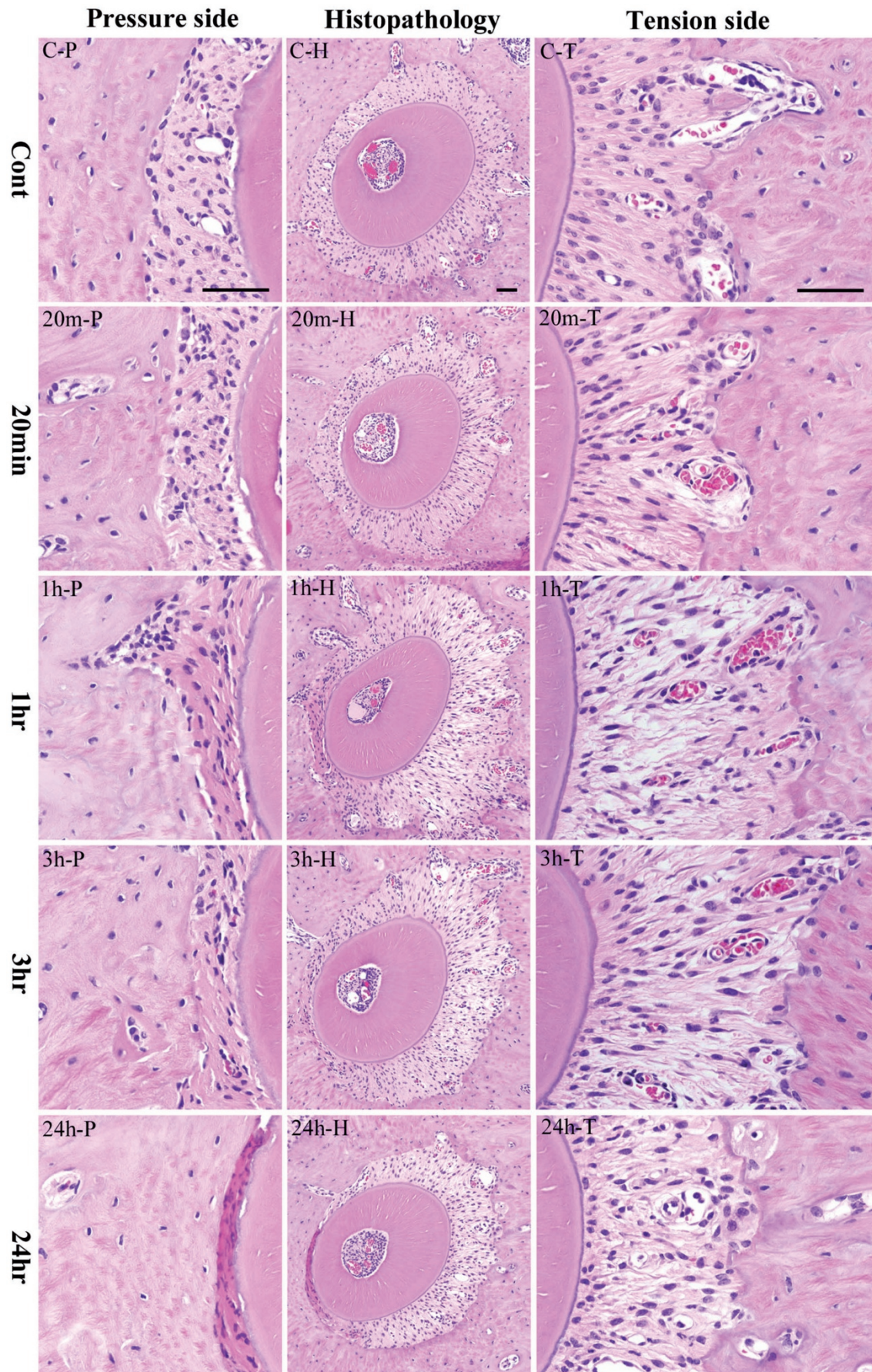


Fig. 4. Histopathological results. Center column shows histopathological image of the alveolar bone socket morphology. Left column is high power-view of pressure side and right column tension side. The most upper row is the control group and the following is the experimental groups of 20 minutes, 1 hour, 3 hours and 24 hours. The inset bar indicates 50µm.

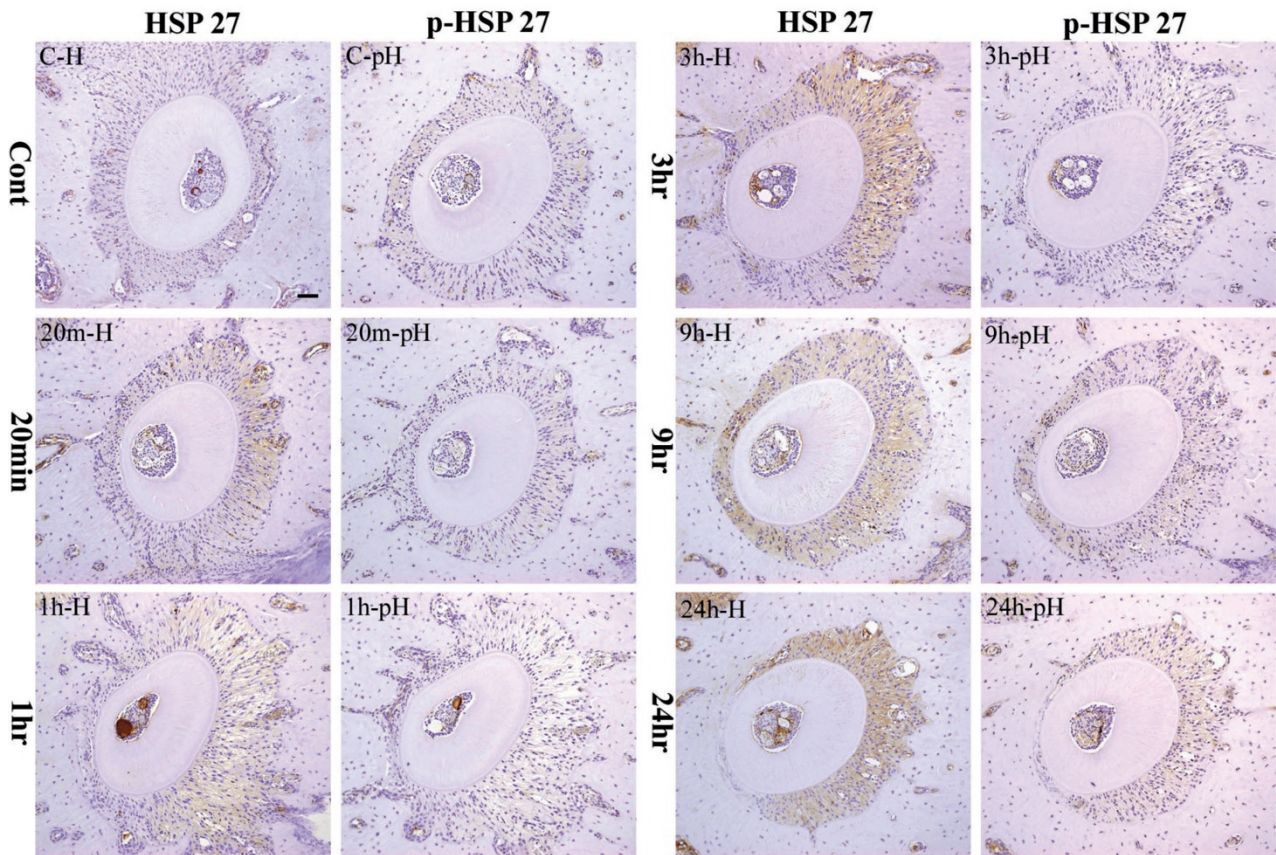


Fig. 5. Immunohistochemical staining profile of HSP27 and p-HSP27 in control and experimental specimens. The inset bar indicates 50µm.

fibroblasts increased its eosinophilic staining; had fewer nuclei per unit area. Osteoblasts lining bone surfaces were also fewer (Fig. 4, 3h-P).

In the 9 hours group, eosinophilic staining of the PDL further increased; the number of PDL fibroblasts decreased. Moreover, some obscure spaces partly in the fiber bundles showed hematoxylin staining caused by karyolysis.

In the 24 hours group, the PDL became strongly eosinophilic. Strong nuclear chromatin condensation or pyknosis has been observed in PDL fibroblasts, karyorrhexis is very evident (Fig. 4, 24h-P).

IMMUNOHISTOCHEMICAL EXAMINATION

Control group

The PDL of the left maxillary distal buccal root of the mouse first molar weakly expressed HSP27 protein. The expression was mainly detected in the cytoplasm of PDL fibroblasts (Fig. 5, C-H). Expression of p-HSP27 was much weaker (Fig. 5, C-pH).

Experimental group

In the 10 minutes group, HSP expression localized in the PDL fibroblasts in the tension side was slightly stronger compared to the control group. On the other hand, the pressure side was almost negative. However, p-HSP27 was negative in both pressure and tension sides.

In the 20 minutes group, cytoplasmic expression of HSP27 on the PDL fibroblasts seen in the tension and

pressure sides was stronger than the 10 minutes group (Fig. 5, 20m-H). There was no change in the p-HSP27 observed when compared to the 10 minutes group (Fig. 5, 20m-pH).

In the 1 hour group, PDL fibroblasts slightly expressed HSP27 stronger compared to the 20 minutes group. No expression was detected in the pressure side (Fig. 5, 1h-H). p-HSP27 was negative in both pressure and tension sides (Fig. 5, 1h-pH).

In the 3 hours group, the PDL fibroblasts and cementoblasts in the tension side strongly expressed HSP27. The expression increased compared to the 1 hour group (Fig. 5, 3h-H). At this point, p-HSP27 expression showed no difference in strength (Fig. 5, 3h-pH).

In the 9 hours group, HSP27 was strongly expressed in the cytoplasm of PDL fibroblasts and cementoblasts as well as in osteoblasts. The expression in the tension side was stronger compared to the 3 hours group (Fig. 5, 9h-H). In this period, p-HSP27 started to become strong in the pressure side (Fig. 5, 9h-pH).

In the 24 hours group, HSP27 was strongly expressed in the tension side by the entire PDL fibroblasts and cementoblasts as well as by osteoblasts. The expression was also stronger compared to the 9 hours group. On the other hand, HSP expression in the pressure side was lost (Fig. 5, 24h-H). Furthermore, the strongest expression of p-HSP27 in the tension side during the whole experiment was detected in this group. In the pressure side, p-HSP27 as well as

Table 2. Expression Strength of HSP 27 and p-HSP27 by IHC

		Time Course						
		Cont	10min	20min	1hr	3hrs	9hrs	24hrs
Tension Side	HSP27	-/+	+	+	+	++	++	+++
	p-HSP27	-/+	-/+	-/+	-/+	-/+	+	++
Pressure Side	HSP27	-/+	-/+	-/+	-	-	++	-
	p-HSP27	-/+	-/+	-/+	-/+	-/+	++	-

Immunopositivity: -: negative; -/+: weak; +: mild; ++: moderate; +++: strong

HSP27 expressions were not detected (Fig. 5, 24h-ph).

Table 2 summarizes the results of the immunohistochemistry.

DISCUSSION

The mechanism of bone formation and resorption using animal experiments during orthodontic tooth movement has already been clarified. Histopathological studies in the tissue changes due to mechanical stress were observed in alveolar bone and PDL in the pressure and tension sides. In recent years, transcription factors that regulate a variety of morphogenetic pathological response and cellular differentiation have been more widely studied [1, 2].

We (Watanabe et al. [3-5]) established the proteins expressed during orthodontic tooth movement by inducing mechanical stress. We investigated the changes in the expressions of Runx2 and Msx2 by the PDL fibroblasts. Msx2 expression was usually weak compared to Runx2 which acted as an inhibitor. The expression of Msx2 was facilitated by Runx2 during the regulation of osteoblast differentiation. However, the response of the cells under mechanical stress has not been investigated.

Therefore, we focused on the expression of various HSPs that maintain homeostasis during injury. HSPs are one of the factors recognized that is transiently enhanced by heat shock [9]. It is also called stress protein because it is not only enhanced by heat shock but also by ischemia, other pathological changes such as infections and inflammation, radiation, physical stress such as light, stress from enzymes, heavy-metal ion, arsenic, arsenic acid, methanol, active oxygen and stress from chemical and various amino acid derivatives [10, 11]. In a study by Ritssa [19], HSPs were induced when the chromosomes of *Drosophila* salivary glands were subjected to high temperatures. Then after, heat shock proteins synthesized in *Drosophila* was first isolated through SDS-PAGE. Some of the major proteins that were also induced by heat shock treatment in non-salivary gland tissues were also collectively considered as HSPs. In addition, puffs from mRNAs of HSPs were transcribed. Later, more advanced researches on HSPs reported that the gene of *E. coli*, yeast and other mammalian cells kept in an environment, subjected to heat stress could preserve the gene [20]. The expression of these HSPs was then proven as a universal phenomenon. HSPs, in ancient times, are proteins acquired in

harsh conditions for the survival of cells, induced by non-physiological stimuli, escape from cell death as molecular chaperone [21] and have a functional anti-apoptotic property [13, 14]. Many HSPs are also expressed by cells in response to stress, inhibition and repair of denatured proteins. HSPs are proteins essential for maintaining life functions of various cells during cell differentiation, growth and existence; are widely-distributed intracellular protein equilibrium and are regularly expressed even in non-stressed conditions in *in vitro* and *in vivo* experiments [14, 21]. HSP is a dozen to several hundreds kDa polypeptides divided by molecular weight and individually named into high-molecular HSPs (families of HSP110, HSP90, HSP70, HSP40-60) and low-molecular HSPs (HSP20 family). The expressions of these HSPs and functions in different sites have been reported so far.

High-molecular weight HSPs such as HSP70, HSP90, etc temporarily binds to proteins in immature state capable of helping the protein to mature and mediates attachments to polypeptides acting as molecular chaperones [22]. Low-molecular HSPs functioning as molecular chaperones have not yet been disclosed [17].

The investigation of HSP27 belongs to the HSP20 family. Originally, HSP27 was found in actin polymerization [23]. HSP27 are known to be present at high levels in vascular smooth muscle and skeletal muscle cells in non-stimulated state. From this, HSP27 is thought to play a role in maintaining blood pressure and other physiological activities in the vascular system [24].

In addition, Kozawa et al. [25], reported that non-stimulated osteoblast-like MC3T3-E1 cells expressed very low levels of HSP27 (3.5-7.4 ng/mg protein) and has been thought to be involved in controlling the proliferation of osteoblasts. HSP27 is expressed during orthodontic tooth movement particularly in the tension side.

HSP27 functions through a process that is phosphorylated by the action of various kinases (p-HSP27). In osteoblasts, TGF- β 1 (transforming growth factor beta 1) is phosphorylated by the action of hydrogen peroxide [26] or by p38MAPK (p38MAPK kinase) [27]. p38 MAPK was phosphorylated by HSP27 and is thought to be working with HSP27 necessary for the protection of various proteins formed from 140-800 kDa oligomers [28], preventing apoptosis during early stages and cell differentiation [29-31]. In this study, we also examined p-HSP27.

First, with the induction of mechanical stress without specific time, Reitan [32] reported that bone for-

mation begun 1 to 2 days as a response after simple mechanical stress was applied due to rapid cell-mediated bone remodeling. In addition, temporal expressions of HSP27 and HSP70 polypeptide by PDL cells to mechanical stress have been confirmed [6]. From these things, expressions of HSP27 and p-HSP27 within 24 hours are thought to be involved in cell differentiation. Moreover, Watanabe et al. [3] reported that 20 minutes after mechanical stress applied on mouse molar, the PDL fibroblasts strongly expressed Runx2 and Msx2 in the tension side which increased over time. In this regard, we compared the data of Watanabe et al. [3] from 10 minutes to 24 hours after inserting the rubber dam sheet.

Firstly, histological examination was performed with hematoxylin and eosin stain comparing the control and experimental groups where mechanical stress was induced in the experimental group. Mechanical stress was initially induced at 20 minutes; root relative movement was set up in 3 hours. The PDL space is narrower in the pressure side. Degenerative changes and increased in eosinophilic staining of PDL fibroblasts were observed. PDL fibroblasts nucleus was strongly flattened causing karyolysis. Our findings were similar to those previously described [3-5, 8].

Immunohistochemical examination was also included in this study. The cytoplasm of the PDL fibroblasts in the distal buccal root of the left maxillary first molar control mice showed weak activity of HSP27 and p-HSP27. Permanent tooth is suffering from mechanical stress due to mastication thousands of times a day. In these circumstances, the supporting PDL maintains its physiological state. In the control group, HSP27 and p-HSP27 are believed to maintain homeostasis of the PDL during physiological function. Similar to reports, HSP27 exists in this non-stress working to maintain homeostasis [14, 21].

When HSP27 and p-HSP27 expression was examined in the experimental group subjected to mechanical stress, PDL fibroblasts expressed HSP27 stronger compared to the control group in the tension side after 10 minutes. HSP27 positive response increased over time; HSP response in 9 hours group on the pressure side increased further by PDL fibroblasts and osteoblasts. Similar to previous reports, HSP is believed to have been involved in repair of cellular damage from injury, damage and various degenerative changes in PDL fibroblasts due to mechanical stress [14, 21]. However, p-HSP27 expression was a bit delayed. This finding suggests that p-HSP27 might function as a molecular chaperone.

Moreover, in the HSP27 expression in 24 hours group; cementoblasts, osteoblasts and the entire PDL fibroblasts in the tension side strongly expressed HSP27. HSP expression in 24 hours group, in the tension side is more intense compared to 9 hours group. It is thought that HSP27 gained its peak between 9 to 24 hours after mechanical stress induction. Also, little variation in the staining of the cytoplasm and nucleus was noted. However, the variation was not clear. p-HSP27 expression in the tension side was the strongest among groups. These reactions are thought to be induced by mechanical stress on the PDL.

In non-stimulated osteoblast-like MC3T3-E1 cells, HSP27 levels were very low (3.5-7.4 ng/mg protein) and that HSP27 was considered to be involved in controlling the proliferation of osteoblasts. Now, in search for HSP27 and p-HSP27 timing expression, the weak expression in the PDL was kept at low levels when not subjected to mechanical stress. This *in vivo* experiment validates the *in vitro* data of Kozawa et al. [25]. In addition, after mechanical stress, HSP27 and p-HSP27 were expressed about the same period of time as Runx2, Msx2 and ALP as previously reported by Watanabe et al. [3]. This suggests that HSP27 and p-HSP27 are working as molecular chaperones causing bone formation by activating osteoblasts.

In the pressure side of the 24 hours group, HSP27 and p-HSP27 expressions almost entirely disappeared. Those histological findings are also consistent with the degenerative changes in PDL fibroblasts produced in the pressure side. Moreover, the intense HSP27 expression by the PDL fibroblasts in the tension side more than the 9 hours group was brought by their response to mechanical stress to the cells producing a variety of proteins though long-standing pressure caused the death of other cells. Thus, the force exerted was too much for the PDL and the continuous heat produced due to pressure was not suitable.

In summary, the study suggests that HSP27 has been closely involved in the repair of tissue to maintain homeostasis of the periodontal tissues by the activation of PDL fibroblasts. Also, the data of this study adds to the existing trend in role of Msx2 and Runx2 in the activation of osteoblasts during bone formation suggesting the role of HSP27 as a molecular chaperone during orthodontic treatment induced by mechanical stress.

Acknowledgment: This research was partially supported in part by a Grant-in-Aid for Scientific Research (C) (#20592419) from the Japan Society for the Promotion of Science.

REFERENCES

1. Saito Y, Yoshizawa T, Takizawa F, Ikegami M, Ishibashi O, Okuda K, Hara K, Ishibashi K, Obinata M, Kawashima H. A cell line with characteristics of the periodontal ligament fibroblasts is negatively regulated for mineralization and Runx2/Cbfa1/Osf2 activity, part of which can be overcome by bone morphogenetic protein-2. *J Cell Sci.* 2002; 115: 4191-4200.
2. Yoshizawa T, Takizawa F, Iizawa F, Ishibashi O, Kawashima H, Matsuda A, Endo N, Kawashima H. Homeobox protein Msx2 acts as a molecular defense mechanism for preventing ossification in ligament fibroblasts. *Mol Cell Biol.* 2004; 24: 3460-3472.
3. Watanabe T, Nakano K, Muraoka R, Shimizu T, Okafuji N, Kurihara S, Yamada K and Kawakami T. Role of Msx2 as a promoting factor for Runx2 at the periodontal tension sides elicited by mechanical stress. *Eur J Med Res.* 2008; 13: 425-431.
4. Watanabe T, Okafuji N, Nakano K, Shimizu T, Muraoka R, Kurihara S, Yamada K and Kawakami T. Periodontal tissue reaction to mechanical stress in mice. *J Hard Tissue Biol.* 2007; 16: 71-74.
5. Watanabe T, Nakano K, Shimizu T, Okafuji N, Kurihara S, Yamada K and Kawakami T. Immunohistochemistry of the Periodontal Ligament Fibroblasts in Orthodontic Tension Sides. *J Hard Tissue Biol.* 2009; 18(4): 175-180.

6. Muraoka R, Nakano K, Matsuda H, Tomoda M, Okafuji N, Kurihara S, Yamada K and Kawakami T. Immunohistochemical Observation of Heat Shock Proteins Expression in Mouse Periodontal Tissues due to Orthodontic Mechanical Stress. *J Hard Tissue Biol.* 2009; 18(4): 193-197.
7. Matsuda H, Muraoka R, Tomoda M, Nakano K, Okafuji N, Yamada K and Kawakami T. Immunohistochemical Observation of BMP in the Mouse Orthodontic Periodontal Tension Sides. *J Hard Tissue Biol.* 2009; 18(4): 181-184.
8. Kawakami T, Nakano K, Shimizu T, Kimura A, Okafuji N, Tsujigiwa H, Hasegawa H and Nagatsuka H. Histopathological and immunohistochemical background of orthodontic treatment. *Int J Med Biol Front.* 2009; 15(7/8): 591-615.
9. Milton, J.S. Heat shock proteins. *J Biol Chem.* 1990; 265: 12111-12114.
10. Maeda T, Kameda T and Kameda A. Loading of continuously applied compressive force enhances production of heat shock protein 60, 70 and 90 in human periodontal ligament-derived fibroblast-like cells. *J Jpn Orthod Soc.* 1997; 56: 296-302.
11. Okazaki M, Shimizu Y, Chiba M and Mitani H. Expression of heat shock proteins induced by cyclical stretching stress in human periodontal ligament fibroblasts. *Tohoku Univ. dent. J.* 2000; 19: 108-115.
12. Craig EA, Weissman JS and Horwich AL. Heat shock proteins and molecular chaperones: mediators of protein conformation and turnover in the cell. *Cell.* 1994; 78: 365-372.
13. Arrigo AP and Landry J. Expression and function of the low molecular weight heat shock proteins. In: *The Biology of Heat Shock Proteins and Molecular Chaperones.* Morimoto RI, Tissières A and Georgopoulos C eds, Cold Spring Harbor Laboratory Press, North America, 1994; pp335-373.
14. Lindquist S and Craig EA. The Heat-Shock Proteins. *Annu Rev Genet.* 1988; 22: 631-677.
15. Shigehara S, Matsuzaka K and Inoue T. Morphohistological change and expression of HSP70, osteopontin and osteocalcin mRNAs in rat dental pulp cells with orthodontic tooth movement. *Bull Tokyo Dent Coll.* 2006; 47(3): 117-124.
16. Araujo RMS, Oba Y and Moriyama K. Identification of genes related to mechanical stress in human periodontal ligament cells using microarray analysis. *J Periodont Res.* 2007; 42: 15-22.
17. Benndorf R, Hayess K, Ryazantsev S, Wieske M, Behlke J and Lutsch G. Phosphorylation and supermolecular organization of murine small heat shock protein HSP25 abolish its actin polymerization-inhibiting activity. *J Biol Chem.* 1994; 269: 20780-20784.
18. Waldo CM. Method for the study of tissue response to tooth movement. *J Dent Res.* 1953; 32: 690-691.
19. Ritossa F. A new puffing pattern induced by temperature shock and DNP in drosophila. *Cellular and Molecular.* 1962; 18: 571-573.
20. Miyagawa Y, Lee JM, Maeda T, Koga K, Kawaguchi Y and Kusakabe T. Differential expression of a Bombyx mori AHA1 homologue during spermatogenesis. *Insect Mol Biol.* 2005; 14: 245-253.
21. Hratl FU. Molecular chaperone in cellular protein folding. *Nature.* 1996; 381: 571-579.
22. Gething MJ and Sambrook J. Protein folding in the cell. *Nature.* 1992; 355: 33-44.
23. Miron T, Vancompernelle K, Vandekerckhove J, Wilchek M and Geiger B. A 25-kDa inhibitor of actin polymerization is a low molecular mass heat shock protein. *J Cell Biol.* 1991; 114: 255-261.
24. Inaguma Y, Goto S, Shinohara H, Hasegawa K, Ohshima K and Kato K. Physiological and pathological changes in levels of the two small stress proteins, HSP27 and alpha B crystallin, in rat hindlimb muscles. *J Biochem.* 1993; 114: 378-384.
25. Kozawa O, Niwa M, Matsuno H, Tokuda H, Miwa M, Ito H, Kato K and Uematsu T. Sphingosine 1- phosphate induces heat shock protein 27 via p38 mitogen-activated protein kinase activation in osteoblasts. *J Bone Miner Res.* 1999; 14: 1761-1767.
26. Shibamura M, Kuroki T and Nose K. Cell-cycle dependent phosphorylation of HSP28 by TGF β 1 and H2O2 in normal mouse osteoblastic cells (MC3T3-E1), but not in their RAS-transformants. *Biochem Biophys Res Commun.* 1992; 187: 1418-1425.
27. Kawamura H, Otsuka T, Matsuno H, Niwa M, Matsui N, Kato K, Uematsu T and Kozawa O. Endothelin-1 stimulates heat shock protein 27 induction in osteoblasts: involvement of p38 MAP kinase. *Am J Physiol.* 1999; 277: 1046-1054.
28. Kotlyarov A and Gaestel M. Is MK2 a mitogen-activated protein kinase-activated protein kinase 2? the key for understanding post-transcriptional regulation of gene expression? *Biochem Soc Trans.* 2002; 30: 959_963.
29. Arrigo AP and Preville X. Role of Hsp27 and related proteins. In: *Hand-book of Experimental Pharmacology*, DS Latchman ed, Springer, Berlin-New York, 1999; 101-132.
30. Ciocca DR, Oesterreich S, Chamness GC, McGuire WL and Fuqua SA. Biological and clinical implications of heat shock protein 27,000 (Hsp27) a Review. *J Natl Cancer Inst.* 1993; 85(19): 1558-1570.
31. Mehlen P, Mehlen A, Godet J and Arrigo AP. Hsp27 as a switch between differentiation and apoptosis in murine embryonic stem cells. *J Biol Chem.* 1997; 272: 31657-31665.
32. Reitan K. Tissue behavior during orthodontic tooth movement. *Am J Orthodont.* 1960; 46: 881-900.

Received: June 4, 2010 / Accepted: July 29, 2010

Address for correspondence:

Rina Muraoka, DDS,
Hard Tissue Pathology Unit,
Matsumoto Dental University
Graduate School of Oral Medicine,
1780 Hirooka-Gobara,
Shiojiri, 399-0781 Japan
Phone and Fax: +81-263-51-2035
E-mail: mura@po.mdu.ac.jp