

Multipoint analysis of anatomical condylar movement using dental CT

KENGO TAKEO¹, YUSUKE KOMAZAKI¹, MASANORI HOSHINO^{1,2},
DAIGO KOIDE^{1,2}, AYANE AOKI^{1,2}, TORU KAGEYAMA^{1,2},
AKIRA TAGUCHI³ and KAZUHIRO YAMADA^{1,2}

¹*Department of Orthodontics, School of Dentistry,
Matsumoto Dental University, Shiojiri, Japan*

²*Department of Hard Tissue Research, Graduate School of Oral Medicine,
Matsumoto Dental University, Shiojiri, Japan*

³*Department of Oral and Maxillofacial Radiology, School of Dentistry,
Matsumoto Dental University, Shiojiri, Japan*

Summary

The aim of this study was to develop a method for integrating morphological coordinates obtained with dental computer tomography (CT) and jaw movement coordinates acquired with a mandibular movement measuring device in order to enable multipoint analysis of anatomical condylar movements to be performed.

The study subjects were two volunteers. One of the subjects displayed mandibular deviation and had a deformed condyle (on the deviated side), while the other subject exhibited normal occlusion and had healthy condyles. We placed three lead markers in front of each of the subjects' ears and used them to integrate dental CT-derived morphological volume data and jaw movement data, both of which were obtained while the subjects were in the same seated position.

Regarding the reproducibility of the reference point data, the positioning and orientation data obtained with the condylar movement measurement system exhibited maximum standard deviation values of 0.162 mm and 0.074°, respectively, while the equivalent data acquired with the CT coordinate system displayed maximum standard deviation values of 0.068 mm and 0.007°, respectively. This suggested that reference point errors had little effect on our multipoint analysis of anatomical condylar movement and that the method used to transform the CT coordinates was highly precise.

These results indicate that our method for integrating dental CT-derived coordinates with those acquired using a condylar movement measuring device leads to minimal errors in the positional/rotational data for the reference markers and hence, facilitates multipoint analyses of anatomical condylar movement.

Introduction

Condylar movement has been extensively studied using equipment for measuring mandibular movement. In many instances, such analyses have focused on a single representative point such as a particular point on a kinematic axis, an arbitrary condylar point, or a point on a hinge axis, while several multipoint analyses based on arbitrary condylar points or the intercondylar axis have also been conducted¹⁻⁴.

However, these methods have insufficient accuracy for analyzing condylar movement, as the reference points they are based on only have indirect positional relationships with the actual condyles and do not accurately reflect condylar morphology. In particular, in subjects with mandibular deviation or osteoarthritis of the temporomandibular joint (TMJ) it can be difficult to accurately determine reference points for jaw movement analysis since their condyles are often deformed and the anatomical structure of the condyle is complex. Condylar movement is a complex three-dimensional (3D) process involving both translation and rotation. For rotational movement in particular, single-point based analyses will detect different movements depending on the position of the selected reference point. Therefore, multipoint analyses of anatomical condylar movement are necessary.

Some recent studies have performed analyses of anatomical condylar movement in which anatomical morphological data acquired with computed tomography (CT) and/or magnetic resonance imaging (MRI) were integrated with data obtained using a mandibular movement tracking device with six degrees of freedom. However, in these studies the CT or MRI scans were performed while the subjects were in the dorsal position, whereas the mandibular movement data were acquired while the subjects were seated. A customized facebow was used for coordination integration. Since the position of the customized facebow could have altered due to the changes in the subjects' body positions among the CT, MRI and mandibular movement measurement sessions, reproducibility errors might have occurred⁵⁻⁹.

Therefore, a method for (1) obtaining condylar coordinate data from seated subjects with dental CT and a mandibular movement measuring device and (2) integrating the collected data, was developed in order to enable precise multipoint 3D analyses of anatomical condylar movements. We also used this system to examine the condylar movements of two subjects: one with normal occlusion and one with mandibular deviation.

Subjects and Methods

Subjects

In order to ensure the validity of this research, the subjects were given sufficient explanations regarding its purpose and any associated risks. A total of two subjects (comprising one volunteer and one patient of the Department of Orthodontics of Matsumoto Dental University Hospital), who both gave their consent, were enrolled in this study. The study was conducted with the approval of the Matsumoto Dental University ethical review board (approval number: 0057).

The volunteer subject had normal occlusion (male, age: 28.3 years) and the dental patient exhibited mandibular deviation (female, age: 28.5 years). Both subjects underwent dental CT imaging and the resultant images were used to assess whether their condylar bones had undergone chang-

es. CT did not detect any bone changes in either condyle in the subject with normal occlusion. In the subject with mandibular deviation, the condyle on the deviated side was deformed, but the condyle on the non-deviated side did not exhibit any changes.

Furthermore, MRI did not detect disk displacement in either TMJ in the subject with normal occlusion. In the subject with mandibular deviation, MRI detected anterior disk displacement without reduction on the deviated side and no disk displacement on the non-deviated side.

The subject with normal occlusion exhibited canine-guidance on the working side during lateral excursions in both directions. The subject with mandibular deviation displayed a left deviated mandible and an Angle Class III molar relationship. During left excursions, the upper left premolar, first and second molars and lower left first and second molars made contact on the working side and during right excursions the upper right premolar, first and second molars and lower right first and second molars made contact on the working side. Thus, premolar and molar guidance were observed during both left and right excursions.

Methods

1. Reference marker placement

An equilateral triangle (side length: 20 mm) was created in front each of the subjects' ears using three lead markers in order to facilitate coordinate transformation between the coordinate system used during the imaging of the TMJ on dental CT and that used by the six degrees of freedom jaw movement measurement system to assess condylar movement in three dimensions (Fig. 1). The point located 13 mm anterior to the tragus on the straight line running across the skin from the posterior border of the tragus to the lateral angle of the eye was defined as the arbitrary condylar point and the first marker was placed on there. As for the second point, it was located 20 mm anterior to the arbitrary condylar point on the line passing through the latter point on the eye-ear plane. The third point was located below and between the first two points so as to form an equilateral triangle.

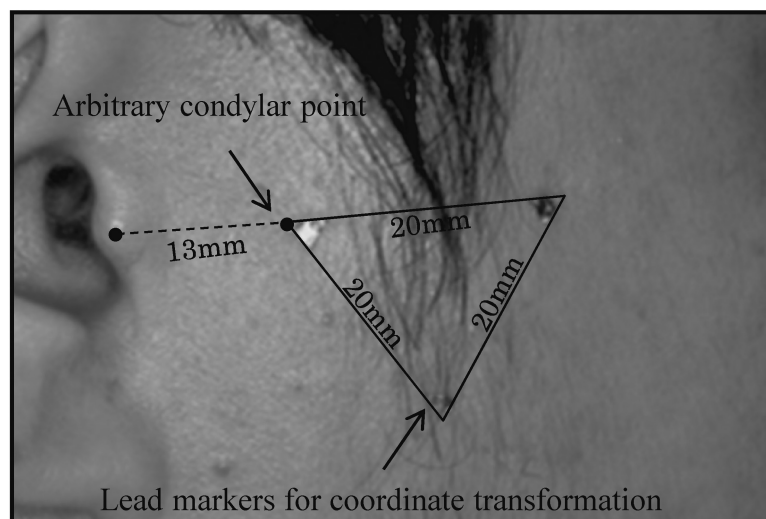


Fig. 1 : Placement of lead markers in front of the subjects' ears to facilitate coordinate transformation.

The point located 13 mm anterior to the tragus on the straight line running across the skin from the posterior border of the tragus to the lateral angle of the eye was defined as the arbitrary condylar point. The point located 20 mm anterior to the arbitrary condylar point on the line passing through the latter point on the eye-ear plane was defined as the second point. The third point was placed below and between the other two so as to form an equilateral triangle.

eral triangle.

2. CT imaging

During the CT imaging, the lead markers were fixed in place and the subjects were seated and kept their mouths in the intercuspal position. A scan was then conducted from above the Frankfort plane using dental CT equipment with a small irradiation field (3D Accuitomo type F17[®], Morita Corporation, Tokyo, Japan, owned by Matsumoto Dental University). The scan table was rotated at 1.0-mm intervals and the diameter and height of the scanned region were 170 mm and 120 mm, respectively. The jaw joint slices were 0.5 mm thick and the slice interval was 0.25 mm (90kV, 5.0 mA, voxel size: 0.25 mm).

3. Measurement of mandibular movement

Jaw movement was assessed using an optical positioning measurement system with six degrees of freedom (MM-J2[®]: Shofu Inc., Kyoto, Japan). The most exterior points of each of the three lead markers fixed to the subjects' skin before the CT imaging were registered as reference points in the jaw movement coordinate system (Fig. 2). After the coordinate registration, lateral excursions were measured at 100 Hz, with the intercuspal position used as the starting point¹⁰. The movements of the incisal and condylar points during lateral excursions were analyzed.

4. Digitization of the CT data

The CT data were input into a workstation (Precision T5500[®]: Dell Japan, Tokyo, Japan) and 3D images were reconstructed. The coordinates of the three lead reference points were determined on reconstructed sagittal, horizontal and frontal plane images using the software i-VIEW (Morita Corporation, Tokyo, Japan). Three condylar analysis points (the outer pole, interior pole and the central condylar point) were also registered in the CT coordinate system. The outer pole and interior pole were defined as the outermost and innermost points of the condyle, respectively, on the sagittal plane images. The central point between the outer and inner poles was defined as the central

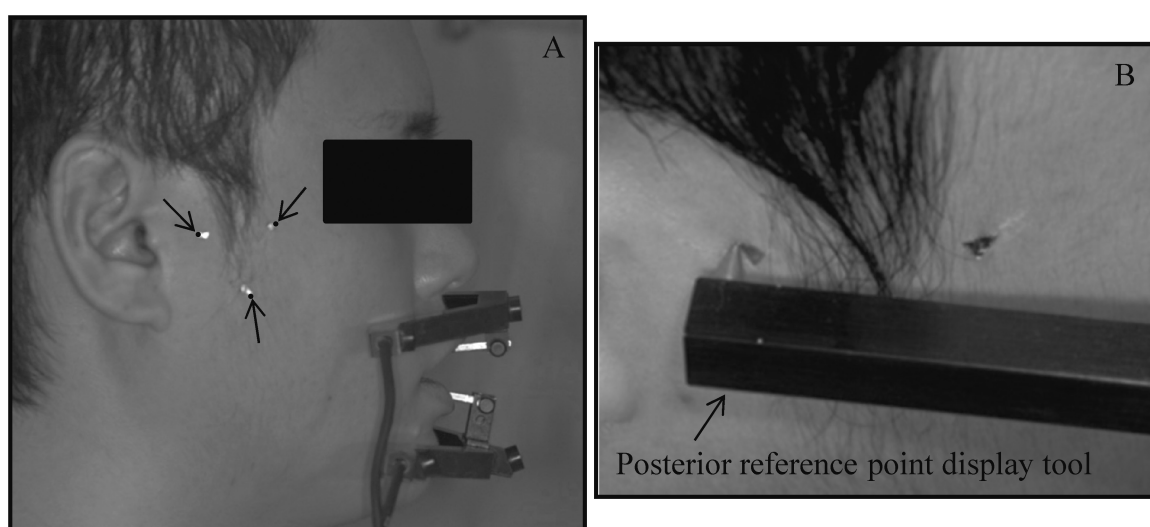


Fig. 2 : Registration of reference points in the jaw movement coordinate system.

A : Three lead markers were placed in front of each ear.

B : The most exterior points of each of the three lead markers prior to the CT imaging were registered as reference points in the jaw movement coordinate system.

condylar point.

5. Coordinate transformation

The outermost points of the three lead markers were used as reference points for integrating the coordinate systems used to plot the dental CT and condylar movement data. For the jaw movement coordinates, the central point between left and right arbitrary condylar points was taken as the starting point. The Y-axis passed through the left and right arbitrary condylar points and the starting point while the X-axis ran straight through the Y-axis, passing through the starting point on the plane formed by the Y-axis and left orbitale. The Z-axis was defined as the axis that passed through the starting point and ran perpendicular to both the X- and Y-axes. The CT starting point was defined as the rotation center.

Coordinate conversion was performed using rotating matrix coefficient (R) obtained by calculation of Euler's angle (Fig. 3). In the following pattern diagrams of Figure 3 describe the coordinate conversion using Euler's angle.

Fig. 3-A shows the original coordinate (X0, Y0, Z0). Fig. 3-A to 3-B show that the first rotation is by an angle φ about the Z0-axis. The coordinate (X0, Y0, Z0) is converted to the coordinate (X1, Y1, Z1, Z0 = Z1).

$${}^0R_1 = \begin{pmatrix} \cos\varphi & -\sin\varphi & 0 \\ \sin\varphi & \cos\varphi & 0 \\ 0 & 0 & 1 \end{pmatrix}$$

Fig. 3-B to 3-C shows that the second rotation is by an angle θ about the former X0-axis (now X1). The coordinate (X1, Y1, Z1) is converted to the coordinate (X2, Y2, Z2, X1 = X2).

$${}^1R_2 = \begin{pmatrix} 1 & 0 & 0 \\ 0 & \cos\theta & -\sin\theta \\ 0 & \sin\theta & \cos\theta \end{pmatrix}$$

Fig. 3-C to 3-D shows that the third rotation is by an angle Ψ about the former Z1-axis (now Z2). The coordinate (X2, Y2, Z2) is converted to the coordinate (X3, Y3, Z3, Z2 = Z3).

$${}^2R_3 = \begin{pmatrix} \cos\Psi & -\sin\Psi & 0 \\ \sin\Psi & \cos\Psi & 0 \\ 0 & 0 & 1 \end{pmatrix}$$

Fig. 3-E shows that the coordinate (X3, Y3, Z3, X3) is converted from the original coordinate (X0, Y0, Z0) using the R.

$$\text{Finally, } {}^0R_3 = {}^0R_1 {}^1R_2 {}^2R_3 = \begin{pmatrix} \cos\varphi & -\sin\varphi & 0 \\ \sin\varphi & \cos\varphi & 0 \\ 0 & 0 & 1 \end{pmatrix} \begin{pmatrix} 1 & 0 & 0 \\ 0 & \cos\theta & -\sin\theta \\ 0 & \sin\theta & \cos\theta \end{pmatrix} \begin{pmatrix} \cos\Psi & -\sin\Psi & 0 \\ \sin\Psi & \cos\Psi & 0 \\ 0 & 0 & 1 \end{pmatrix}$$

$$\begin{bmatrix} \cos\varphi - \sin\varphi\cos\theta & \sin\varphi\sin\theta \\ \sin\varphi & \cos\varphi\cos\theta & \cos\varphi\sin\theta \\ 0 & \sin\theta & \cos\theta \end{bmatrix} \begin{bmatrix} \cos\psi - \sin\psi & 0 \\ \sin\psi & \cos\psi & 0 \\ 0 & 0 & 1 \end{bmatrix}$$

$$\begin{bmatrix} \cos\varphi\cos\psi - \sin\varphi\cos\theta\sin\psi - \cos\varphi\sin\psi - \sin\varphi\cos\theta\cos\psi & \sin\varphi\sin\theta \\ \sin\varphi\cos\psi + \cos\varphi\cos\theta\sin\psi - \sin\varphi\sin\psi + \cos\varphi\cos\theta\cos\psi - \cos\varphi\sin\theta \\ \sin\theta\sin\psi & \sin\theta\cos\psi & \cos\theta \end{bmatrix}$$

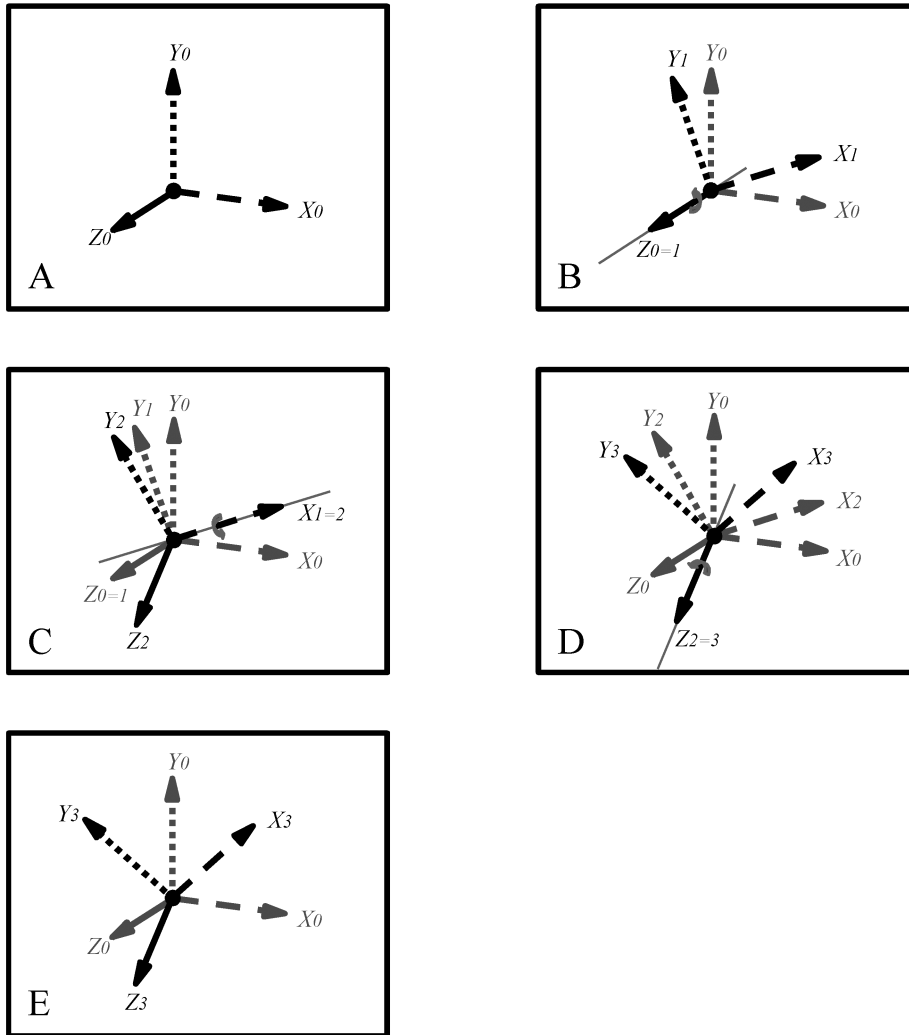


Fig. 3 : Coordinate conversion using rotating matrix coefficient (R) obtained by calculation of Euler's angle.

- A : The original coordinate (X0, Y0, Z0).
A to B : The first rotation is by an angle φ about the Z0-axis. The coordinate (X0, Y0, Z0) is converted to the coordinate (X1, Y1, Z1, Z0=Z1).
B to C : The second rotation is by an angle θ about the former X0-axis (now X1). The coordinate (X1, Y1, Z1) is converted to the coordinate (X2, Y2, Z2, X1=X2).
C to D : The third rotation is by an angle ψ about the former Z1-axis (now Z2). The coordinate (X2, Y2, Z2) is converted to the coordinate (X3, Y3, Z3, Z2=Z3).
E : The coordinate (X3, Y3, Z3, X3) is converted from the original coordinate (X0, Y0, Z0) using the R.

In the present study, coordinate conversion was performed by multiplying the CT coordinates by this rotating matrix coefficient (R) based on the positions of the three lead markers, because the starting points of the CT coordinate system (Σ_{CT}) and jaw measurement coordinate system ($\Sigma_{J(Trans)}$) are different, then adding the parallel movement quantities (Q) for the X, Y and Z axes, which gave the equivalent jaw movement coordinates ($\Sigma_{J(Trans)} = \Sigma_{CT} \times R + Q$) (Fig. 4). The anatomical condylar coordinates calculated with this method were used for the multipoint analysis of anatomical condylar movements.

6. Reproducibility testing

The reproducibility of the measurements obtained using the CT coordinate system (Σ_{CT}) and jaw movement coordinate system ($\Sigma_{J(Trans)}$) was assessed based on the variance values for the rotation of the markers and the positions of the markers relative to the starting point. Therefore, reproducibility was investigated by recording the coordinates of the three lead points five times for each coordinate system and calculating mean values. For each coordinate system, the distances between each reference point and the starting point were measured five times on the X, Y and Z axes and the standard deviation values for each reference point's rotational angles on the X, Y and Z axes were also calculated.

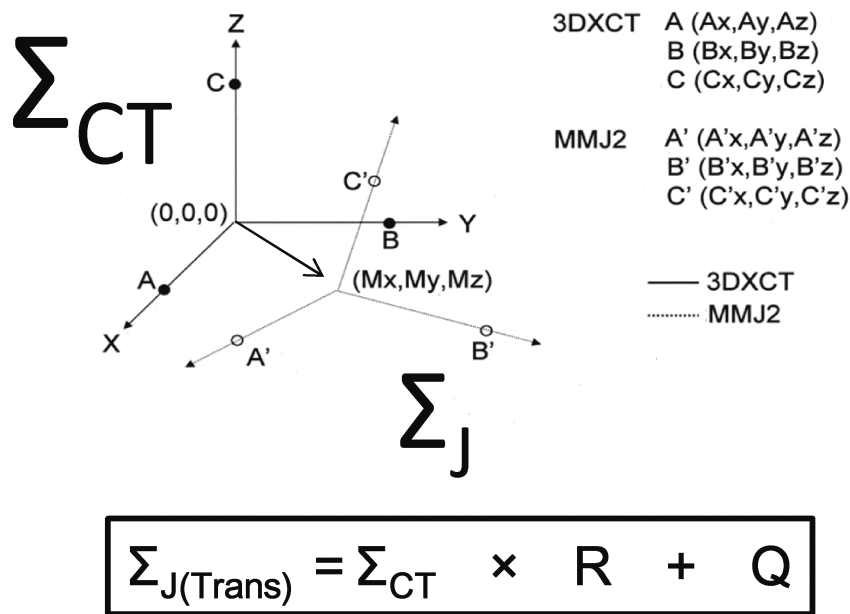
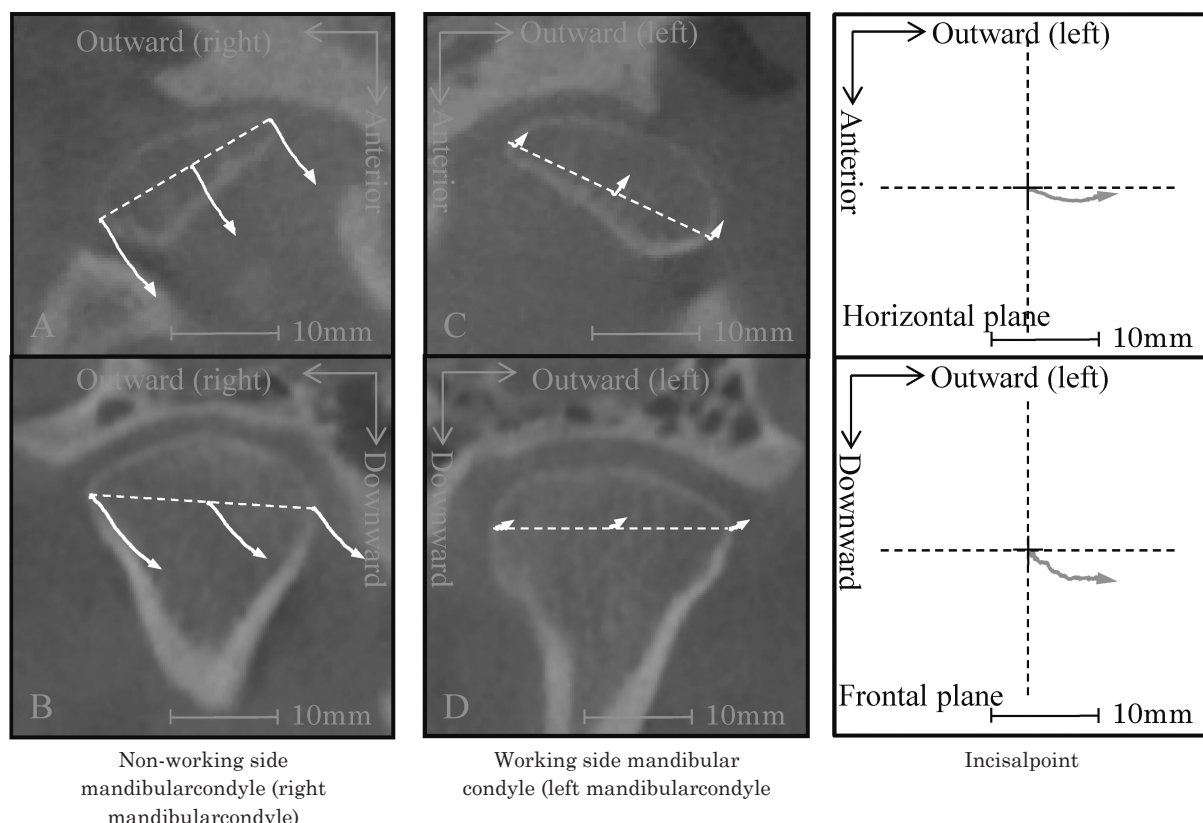


Fig. 4 : Coordinate transformation.
 Coordinate conversion was performed by multiplying the CT coordinate system by the rotating matrix coefficient (R) using the three lead markers and because the CT coordinate system (Σ_{CT}) and jaw measurement coordinate system ($\Sigma_{J(Trans)}$) starting points different, adding parallel movement quantity (Q) towards XYZ thereby converting the coordinates to the jaw movement coordinate system.
 Σ_J : Jaw movement coordinate system
 Σ_{CT} : CT coordinate system
 R : Rotating matrix coefficient
 Q : Parallel translation quantity



Non-working side
mandibularcondyle (right
mandibularcondyle)

Working side mandibular
condyle (left mandibularcondyle)

Incisalpoint

Fig. 5 : Subject with normal occlusion: Trajectories of the condyle and incisal point during left lateral excursions. The arrowheads show the trajectories of the outer pole, central point and inner pole of the condyle and the incisal point. A and C: Horizontal plane including outer and inner poles. Dotted line shows frontal plane including outer and inner poles. B and D: Frontal plane including outer and inner poles, dotted line shows horizontal plane including outer and inner poles.

In non-working side, the outer pole, central point and inner pole of the condyle moved anteriorly, downward and in the mesial direction. The distance moved decreased from the exterior pole to the inner pole.

In Working side, the inner pole exhibited the least movement in the posterior and outward directions, whereas the outer pole demonstrated the greatest movement in these directions, which suggested that a rotational movement centered on the inner pole was being performed.

The incisal point moved anteriorly, toward the working side and downward.

Results

1. Reproducibility testing

1) Orientation (Table 1-A)

In the assessment of the reproducibility of the orientation data obtained with the jaw movement measuring system, it was found that the standard deviation and maximum values for the three orientation parameters (roll, pitch and yaw) ranged from 0.014° to 0.074° and from 0.278° to 0.446°, respectively. As for the reproducibility of the orientation data obtained with CT, the standard deviation and maximum values for the three orientation parameters ranged from 0.001° to 0.007° and from 0.166° to 0.179°, respectively.

2) Position (Table 1-B)

In the assessment of the reproducibility of the positioning data, it was demonstrated that the

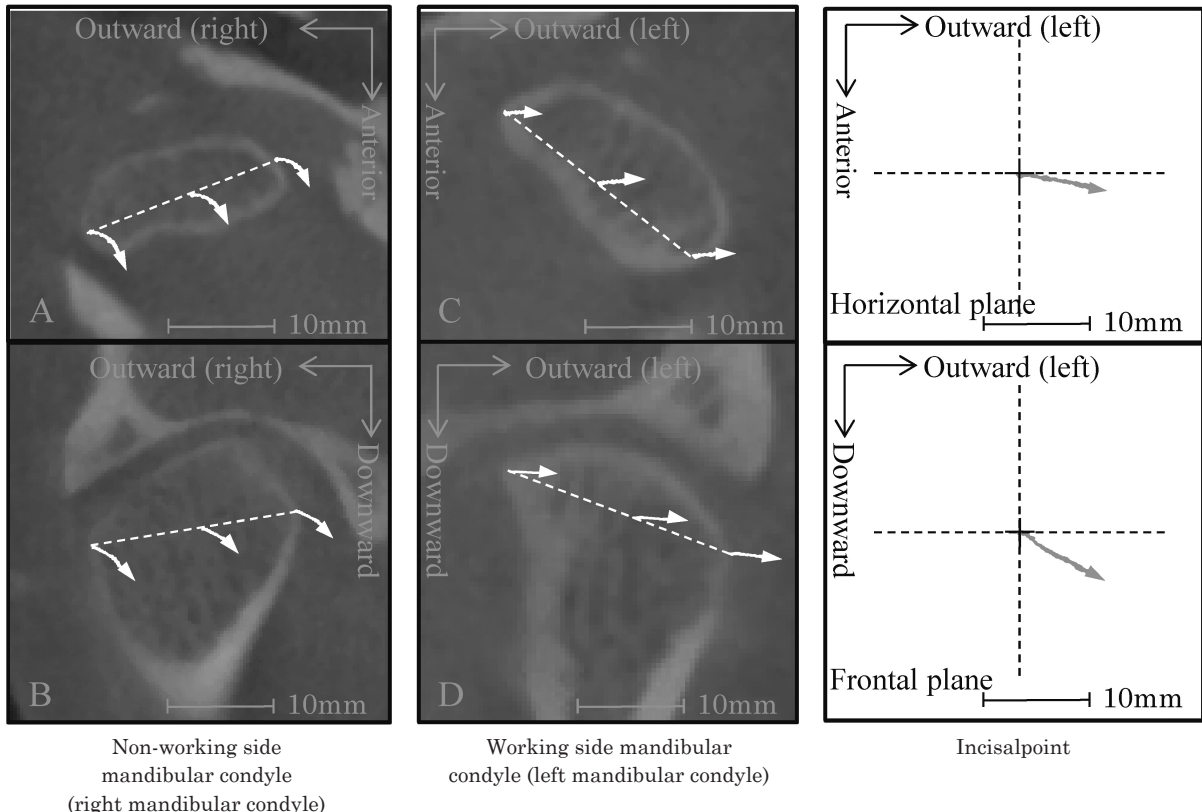


Fig. 6 : Subject with mandibular deviation: Trajectories of the condyle and incisal point during left lateral excursions. A, B, C and D show the same image of plane as showed in Fig. 5.
 In non-working side, as was found in the subject with normal occlusion, the distance moved decreased from the outer pole to the inner pole.
 In working side, the outer pole, central point and inner pole of the condyle moved outwards.
 As was found in the subject with normal occlusion, the incisal point moved anteriorly, toward the working side and downward.

Table 1 : Reproducibility of the jaw movement and CT coordinates.

A: Orientation

Measurements		Orientation (degree)		
		Roll	Pitch	Yaw
Jaw movement data	SD	0.014	0.037	0.074
	Maximum value	0.278	0.446	0.381
CT data	SD	0.001	0.007	0.005
	Maximum value	0.166	0.179	0.169

B: Position

Measurements		Position (mm)		
		x	y	z
Jaw movement data	SD	0.162	0.095	0.069
	Maximum value	0.424	0.245	0.152
CT data	SD	0.068	0.066	0.060
	Maximum value	0.135	0.138	0.130

standard deviation values for the jaw measurement data ranged from 0.069 mm to 0.162 mm, whereas those for the CT data ranged from 0.060 to 0.068 mm.

2. Multipoint analysis of anatomical condylar movement

The incisal and condylar movement pathways recorded during left lateral excursions in the subject with normal occlusion and the subject with mandibular deviation are shown in Figures 5 and 6, respectively. In the subject with normal occlusion, left excursions were guided by the upper and lower canines on the working side. During such excursions, the incisal point moved 1.80 mm in the anterior direction, 3.28 mm downward and 7.04 mm toward the working side. Regarding the condyle on the working side, the exterior pole moved 1.41 mm in the posterior direction, 1.17 mm outwards and 1.19 mm upwards. The central condylar point moved 1.28 mm in the posterior direction, 1.16 mm outwards and 1.16 mm upwards. The inner pole moved 1.13 mm in the posterior direction, 1.13 mm outwards and 1.15 mm upwards. Thus, among the outer pole, central point and inner pole of the condyle, the outer pole exhibited the greatest amount of movement in the anteroposterior, horizontal and vertical directions.

As for the condyle on the non-working side, the outer pole moved 6.02 mm in the anterior direction, 3.42 mm in the mesial direction and 7.95 mm downward. The central condylar point moved 5.84 mm in the anterior direction, 3.36 mm in the mesial direction and 7.81 mm downward. The inner pole moved 5.64 mm in the anterior direction, 3.32 mm in the mesial direction and 7.62 mm downward. Thus, the mean distances decreased from the exterior pole to the inner pole.

In the subject with mandibular deviation, excursions to the deviated (left) side were guided by the upper left premolar, first and second molars and lower left first and second molars. During such excursions, the incisal point moved 1.37 mm in the anterior direction, 6.58 mm toward the working side and 4.25 mm downward. Regarding the condyle on the working side, the exterior pole moved 0.77 mm in the posterior direction, 2.71 mm outwards and 1.47 mm downward. The central condylar point moved 0.67 mm in the posterior direction, 2.68 mm outwards and 1.44 mm downward. The inner pole moved 0.58 mm in the posterior direction, 2.63 mm outwards and 1.39 mm downward. Thus, all three points moved further in the horizontal direction than in the other directions. As for the condyle on the non-working side, the exterior pole moved 2.47 mm in the anterior direction, 3.29 mm in the mesial direction and 4.62 mm downward. The central condylar point moved 2.22 mm in the anterior direction, 3.40 mm in the mesial direction and 4.66 mm downward. The inner pole moved 2.05 mm in the anterior direction, 3.47 mm in the mesial direction and 4.67 mm downward. Thus, just as was found in the subject with normal occlusion, the degree of movement decreased from the outer pole to the inner pole.

Discussion

1. Reproducibility of the multipoint analysis measurements

In previous studies, multipoint analyses of anatomical condylar movements have been conducted using CT^{5,9)}, MRI⁶⁻⁸⁾ and six degrees of freedom jaw movement tracking equipment. However, changes in the subject's position between the imaging and jaw movement tracking sessions cause positional differences in the markers used for coordinate integration, making it possible for errors to occur. To solve this problem, in the present study we integrated dental CT and jaw movement coordinates that had both been obtained while the subjects were seated in the same position. After

measuring mandibular movement during lateral excursions, a coordinate transformation formula was used to transform the CT coordinates for the condylar outer pole, inner pole and central condylar point into jaw movement coordinates and a multipoint analysis of anatomical condylar movement was conducted.

Multipoint analysis of jaw movement using anatomical condylar coordinates has been reported by Tanaka et al.⁵⁾, Krebs et al.⁶⁾ and Hosogai et al.⁹⁾. Tanaka et al.⁵⁾ used equipment comprised of stainless steel wire markers attached to an acrylic board to combine jaw movement tracking data obtained with a six degrees of freedom measurement system with data collected from reconstructed images derived from jaw joint X-rays. Krebs et al.⁶⁾ used three spherical reference markers containing extra-oral contrast liquid to combine reconstructed MRI jaw joint imaging data with mandibular movement data. Hosogai et al.⁹⁾ analyzed some of the problems that arose in the latter two studies. Namely, they investigated the reproducibility of coordinate registration with helical CT and a facebow for tracking jaw movement with six degrees of freedom.

In the above three studies, the imaging was performed while the subjects were in the dorsal position, whereas the jaw movement measurements were obtained while the subjects were seated. Therefore, the changes in the subjects' positions would have altered the position of the customized facebow used for the coordinate integration. This might have caused reproducibility errors during the coordinate integration. In order to solve this problem, in the present study we used dental CT, which can be performed while the subject is seated. This made it possible to perform both the CT imaging and jaw movement recording while the subjects were seated, minimizing the positional changes in the lead reference markers.

The reproducibility of coordinate integration is considered to influence: (1) the reference point reproducibility of jaw movement measurement systems, (2) the accuracy limit of jaw movement measurement systems, (3) the reference point reproducibility of CT coordinate systems, and (4) the accuracy of dental CT imaging.

Our results showed that (1) the positioning and orientation data obtained with the jaw movement measurement system exhibited maximum standard deviation values of 0.162 mm and 0.074°, respectively. In a previous study¹²⁾ involving jaw movement tracking and helical CT imaging, which were performed while the subjects were in different positions, the positioning and orientation data obtained with the jaw movement measurement system displayed maximum errors of 0.64 mm and 0.52°, respectively.

Thus, the greater precision was achieved in the present study. As for the accuracy limit of the jaw movement measurement device, it was reported that positional measurements obtained with the jaw movement measurement device used in the present study exhibited a low root mean square (RMS) error value (0.178 mm)¹⁰⁾.

Regarding the reference point reproducibility of the CT coordinate system used in the present study, the positional and orientation data obtained with dental CT demonstrated maximum standard deviation values of 0.068 mm and 0.007°, respectively, which indicates that dental CT is more accurate than helical CT (maximum standard deviation values for helical CT: 0.27 mm and 0.27°, respectively)⁹⁾.

Concerning the accuracy of dental CT imaging, it has been reported that it exhibits high reproducibility and extremely small error values. In fact, previous studies have reported that it displayed accuracy of ± 0.3 mm compared with actual measurements¹¹⁻¹³⁾.

The above results suggest that errors have minimal effects on anatomical condylar movement

analysis based on coordinate transformation between dental CT images and jaw movement data obtained while the subjects were in the same seated position.

The unification of the coordinate systems of dental CT systems and six degrees of freedom jaw movement measuring devices facilitates the multipoint analysis of anatomical condylar points during small rotational movements such as those performed by the working side condyle during lateral excursions. During such movements, different parts of the condyle undergo different movements and so single point analyses are insufficient for assessing small rotational condylar movements.

2. Multipoint analysis of anatomical condylar movements

The following results in Figures 5 and 6, Normal working side condyles usually undergo rotational movements during lateral excursions. As different parts of the condyle move in different ways during rotational movements, we performed a multipoint analysis of the anatomical movements of the working side condyle using a normal condyle in a subject with normal occlusion and a deformed condyle in a patient with mandibular deviation.

Regarding the working side condyle of the subject with normal occlusion, multipoint analysis of its anatomical movement showed that the inner pole exhibited the least movement in the posterior and outward directions, whereas the outer pole demonstrated the greatest movement in these directions. These results suggest that a rotational movement centered on the inner pole was being performed. Thus, in the subject with normal occlusion left lateral excursions were guided by the working side canines and as the incisal point moved in the anterior, downward and outward directions, the non-working-side condyle moved anteriorly, downward and toward the mesial direction (in a sliding motion) and the working side condyle rotated in a posterolateral direction centering on the inner pole.

In the subject with mandibular deviation, multipoint analysis showed that during lateral excursion of the working side condyle to the deviated side the inner pole, central condylar point and outer pole moved outwards (in a sliding motion) by approximately the same amount. Thus, when lateral excursions were conducted by the subject with mandibular deviation, working side premolar- and molar-guided occlusion in which the incisal point moved in the anterior, downward and outwards directions was observed, the non-working-side condyle exhibited anterior, downward and mesial movements, and the working side condyle moved outwards. In these two cases, the guiding teeth tended to be related to the condylar movement being performed. However, we need to investigate this further using an increased number of cases.

The working side condylar movement observed in the present study appeared to be related to the structure of the TMJ and functional elements such as the guiding teeth during lateral excursions, morphological differences between the right and left condyles and articular fossae¹⁴⁾, articular disk displacement and deformation, slackness caused by the lateral ligament of the TMJ and functional actions that compensate for left and right skeletal morphological deviations. Patients with mandibular deviation often display symptoms of TMJ disorder^{15,16)}, while accompanying condylar bone changes on the deviated side and disk deviation are also common^{15,16)}. In the present study, the subject with mandibular deviation demonstrated anterior disk displacement without reduction on the deviated side on MRI and CT detected bone deformities in the condyle on the deviated side. The results of this study showed that during lateral excursions, the latter subject's working side condyle moved markedly outwards, placing a burden on her condyle, articular disk and articular capsule. This might have played a role in the condylar deformity and anterior disk displacement without re-

duction exhibited by the patient.

Acknowledgements

This study was approved by the ethics committee of Matsumoto Dental University (no: 0057) and was supported by a Grant-in-Aid for Scientific Research (25463205) from the Ministry of Education, Culture, Sports, Science, and Technology, Japan.

References

- 1) Beck HO and Morison WE (1956) Investigation of an arcon articulator. *J Prosthet Dent* **6**: 359–72.
- 2) Kohno S (1983) Dependence of anterior tooth guidance on the condyle path. *Dtsch Zahnarztl Z* **38**: 706–8.
- 3) Hayasaki H, Saitoh I, Iwase Y, Inada E, Hasegawa H, Tokutomi J, Matsumoto Y and Yamasaki Y (2008) Movement of the instantaneous center of rotation and the position of the lateral excursion center during lateral excursion. *Cranio* **26**: 253–62.
- 4) Tokiwa H, Nakazawa F, Ozaki M and Nakamura Y (2010) Anatomical location of various condylar points for jaw movement analysis in Japanese women. *J Oral Rehabil* **37**: 235–41.
- 5) Tanaka H (1992) Three-Dimensional Reconstruction of Temporomandibular Joint Osseous Components Using Tomography and Analysis of Condylar Movements with Six Degrees of Freedom (in Japanese). *J Jpn Prosthodont* **36**: 264–78.
- 6) Krebs M, Gallo LM and Airolidi RL (1994) Three-dimensional animation of the temporomandibular joint. *Technol Health Care* **2**: 193–207.
- 7) Palla S (1997) Jaw tracking and temporomandibular joint animation. *Science and practice of occlusion in Science and Practice of Occlusion*: 365–78. Quintessence Publishing Co. Inc., Chicago.
- 8) Gallo LM, Chiaravalloti G, Iwasaki LR, Nickel JC and Palla S (2006) Mechanical work during stress-field translation in the human TMJ. *J Dent Res* **85**: 1006–10.
- 9) Hosogai A, Hayashi T, Kohno S, Yamada K, Maruyama T and Itoh A (2008) A Precise and Useful Method for Coordinating Computed Tomography and Jaw Movement Frames of Reference. *J Jpn Prosthodont* **52**: 529–36.
- 10) Ogawa T, Shigeta Y, Ando E, Hirai S, Suma M, Hirabayashi R, Ikawa T, Hosoda Y, Araki J, Itoh K, Kamei S, Fukushima S, Moriyama T, Saito I and Kumeda H (2006) Application of a Jaw Motion Tracking Device That Measures Six Degrees of Freedom Using Optoelectronic (in Japanese). *J Jpn Prosthodont* **50**: 210–8.
- 11) Arai Y, Hashimoto K, Iwai K and Shinoda K (2000) Fundamental Efficiency of Limited Cone-beam X-ray CT (3DX Multi Image Micro CT) for Practical Use (in Japanese). *Dent Radiol* **40**: 145–54.
- 12) Suomalainen A, Vehmas T, Kortensniemi M, Robinson S and Peltola J (2008) Accuracy of linear measurements using dental cone beam and conventional multislice computed tomography. *Dentomaxillofac Radiol* **37**: 10–7.
- 13) Yoshida Y, Morita Y, Honda E, Tomotake Y and Ichikawa T (2009) Evaluation of Measurement Accuracy in Imaging Using a Cone-beam CT (in Japanese). *J Jpn Soc Oral Implant* **22**: 3–14.
- 14) Yahata M, Yamada, Hayashi T and Saito I (2009) Unilateral condylar bone deformity and slope of articular eminence related to mandibular asymmetry. *Cranio* **27**: 261–7.
- 15) Uy-Co ET, Yamada K, Hanada K, Hanada K, Hayashi T and Ito J (2000) Condylar bony change and mandibular deviation in orthodontic patients – using helical CT and MRI. *Clin Orthod Res* **3**: 132–43.
- 16) Yamada K, Hanada K, Hayashi T and Ito J (2000) CT Condylar bony change, disc displacement and signs and symptoms of TMJ disorders in orthognathic surgery patients. *Oral Surg Oral Med Oral Pathol Oral Radiol Endod* **91**: 603–10.