
Involvement of Heat-Shock Proteins During Periodontal Ligament Remodeling

Rina Muraoka, Keisuke Nakano,
Hidetsugu Tsujigiwa, Hitoshi Nagatsuka,
Hirokazu Matsuda, Mihoko Tomida,
Norimasa Okafuji, Kazuhiro Yamada and
Toshiyuki Kawakami

Additional information is available at the end of the chapter

<http://dx.doi.org/10.5772/intechopen.79200>

Abstract

Mechanical stress induces various molecules such as heat-shock protein (HSP), which causes structural changes in the proteins in periodontal ligament (PDL). We carried out an experiment to induce traumatic occlusion in mouse PDL and analyzed the expression of HSPs. HSPs investigated acts differently depending on the time of expression. HSPs are constitutively expressed in the PDL and defend cells from stress and maintain homeostasis under normal conditions. During bone addition to the PDL on the tension side, HSP27 and HSP47, HSP70 also acts as molecular chaperone, which assists the maturation of bone morphogenetic proteins and aids osteoblast activation. In HSP 70 and HSP 47, mechanical stress is applied to the PDL on the tension side for a short period of time for alveolar bone repairing, and when abnormality occurs in the collagen structure fibroblasts of PDL, it functions at the injured site, whereby extracellular that promotes abnormal collagen secretion and stores the modified protein in the endoplasmic reticulum, there by controlling the decalcification of PDL. In other words, HSP47 and HSP70 are expressed in PDL fibroblasts on the pressure side damaged by application of mechanical stress and contribute to the repair of collagen tissue by activating PDL fibroblasts, supporting recovery from cell damage.

Keywords: periodontal ligament, mechanical stress, homeostasis, heat-shock proteins, HSP, fibroblasts, collagen tissue, immunohistochemistry, occlusal trauma

1. Introduction

The periodontal tissue responds to different types of stimulus such as mechanical stress and inflammation, to maintain homeostasis, and expresses various proteins to bring about active remodeling of the periodontal tissue [1–12]. Periodontal connective tissue remodeling occurred due to traumatic occlusal overload [13, 14]. Heat-shock proteins (HSPs) reply to mechanical stress, and it is learned about as the main protein manifested by various systems and organizations. HSP is also led by an inflammation, a physical stress, a chemical stress and a pathological change in heat shock [15]. But, the function of each HSP is still unclear. HSP participates in defense and restoration of an injury cell, and it is thought that it contributes to the control of cellular function [16–18]. The main ingredient of a cell outside matrix of PDL is the collagen, and this acts on it so that mechanical stress of bite force and the mechanical correction power may be eased. When a collagen fiber of PDL suffers damage by mechanical stress, and mechanical stress is freed once, a collagen fiber returns to the original shape. However, many points are unclear about the cell protein which contributes to recovery mechanism. In the remodeling course, the fibroblasts play an important role, such as collagen synthesis. HSP47 is a collagen-binding stress protein that acts as a collagen-specific molecular chaperone during the biosynthesis and secretion of procollagen. Type I collagen is a major component of periodontal ligaments [19–21].

We focused on collagen synthesis and HSP47, which are essential to the development of mouse and humans. We developed an experimental model by exposing the periodontal tissue to occlusal overload, and the expression of HSP47 was determined using immunohistochemistry (IHC). Then, we carried out an immunohistochemical investigation of HSP47 expression state in mouse PDL tissue after applying a mechanical stress and during the recovery of the PDL.

2. Materials and methods

Before the experiments: Anesthesia was induced in the mouse by inhalation of a gaseous mixture of isoflurane and air (preanesthetic concentration 4.0%). The experiment animal were using gas anesthesia system for insensitivity to pain by the administration of lower concentration gases before experiment. Gas anesthesia system was control with the fixed current velocity, it was became stable, and the experiment was conducted under the maintained opiate. The upper part of body of a mouse was lifted and fixed on the experimental platform after anesthesia. General anesthesia was maintained during an experiment using an induction pipe through a nose of a mouse (maintenance anesthetic density 1.0%). The upper and lower jaw of the mouse was fixed on the laboratory table to do while opening the mouth of a mouse during an experiment. We prepared the specimen after completing loading occlusal trauma and mechanical stress on the maxillary molar part of the mouse.

Experimental animals: Seventy 8-week-old male ddY mouse (body weight 35 ± 5 g) was used in this study. The mouse was kept in an environment controlled by an air-conditioning unit, in metal cages with bedding on the floor.

This study was planned according to the Matsumoto Dental University (MDU) Experimental Animal Guidelines. This protocol followed the MDU Experimental Animal Study Guidelines and was approved by Animal Study Experimental Committee of MDU (Approval No. 179-10, 233-13).

2.1. Load mechanical stress from the vertical direction

Experiments 1 and 2: We made a hole in an occlusal surface of the upper jaw first molar using one-quarter sizes of round bur. After that, stainless micro screw of head diameter 1.7 mm, head thickness 0.5 mm, official diameter 1.0 mm and the full length 3.5 mm was planted. This makes the mandibular first molar opposite cause a prematurity, and an occlusal trauma has been caused. The experimental period continued for 30 days. A change in the periodontal ligament was observed on 1, 4, 7 and 14 days. The untreated maxillary first molar of the mouse served as the control group (Experiment 1). Then after, the micro plus screw was removed at 4 days after implantation and the subsequent tissue changes were observed (Experiment 2).

2.2. Load mechanical stress from lateral direction

Experiments 3 and 4: A separator was inserted by the method of Waldo [22] in order to apply persistent mechanical stress to the upper molar PDL region of the mouse (**Figure 1**). The one from which a rubber weir seat was severed in a square of 2.0×2.0 mm of folding into two was employed as a separator. The upper part molar range of the mouse is sequence of three teeth, and the first molar and the second molar from the near heart side are the third molar. Therefore, a separator was inserted between the first molar of upper right and the second molar. HSP manifestation was estimated using two experimental systems by this study. Mechanical stress has been loaded with the passage of time using a separator. Mechanical stress was released at most 24 h later, and lumping was removed by the upper part molar of a periodontal tissue of a mouse of the range of the problem. We decided to observe total of

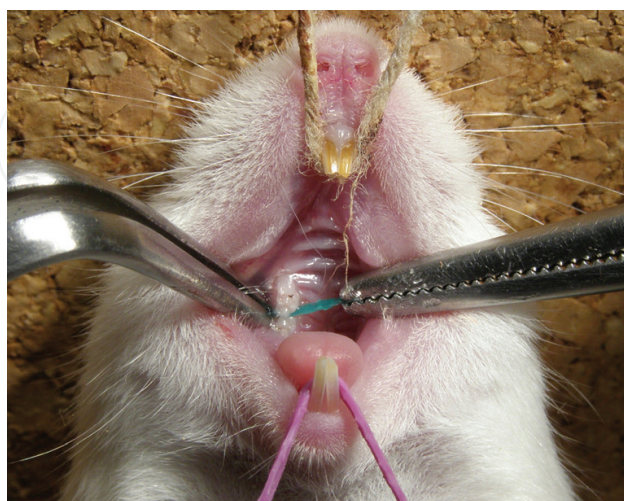

Figure 1. The situation of the insertion. The upper jaw was immobilized by fixing a kite string, and the position of the lower jaw was immobilized by fixing a rubber band. Quotation alteration of literatures #1.

six experimental duration, a group for 10 min (10 min), a group for 20 min (20 min), a group for 1 h (1 h), a group for 3 h (3 h) and a group for 9 h (9 h) and 24 h (24 h) and used five experimental animals per one group. It should be noted that only water was given to a mouse to prevent a separator being dropped during impressing of mechanical stress (Experiment 3).

After loading a mechanical stress by a separator during the 3 hours, and then the stress was released. In the shortest experimental time, an organization that around the maxillary molar and incisors of the mouse have been extracted after 20 minutes later from remove separator. In the longest experimental time was 1 week immediately after removal of a separator. The group in which the tissue was removed immediately after removing the separator (3 h + 0 min, 3 h + 0 min), a 20 min after removing the separator group (3 h + 20 min), a 1 h after removing the separator group (3 h + 1 h), a 3 h after removing the separator group (3 h + 3 h), a 9 h after removing the separator group (3 h + 9 h), a 24 h after removing the separator group (3 h + 24 h), a 3 day after removing the separator group (3 h + 3 d), and a 1 week after removing the separator group (3 h + 1 w), with five mice per group.

A mechanical stress was loaded for 3 hours, and it was released, then we were permitting that the mouse could consuming water and solid feed freely till the end of an experimental period (Experiment 4).

The periodontal tissue of the upper left molar from the same individual mouse (the opposite, untreated side) was used as a control group. For both the experimental and control groups, the distal buccal root of the upper first molar was the observation site by this experiments.

2.3. Tissue preparation

In the four experiments described earlier, the mouse upper molar periodontal tissue was excised together with the jawbone, promptly fixed and immersed for 24 h in a fixing solution. Then after, specimens were decalcified in 10% EDTA solution for 3 weeks. Next, it was embedded in paraffin.

Experiments 1 and 2: This was followed by embedding in paraffin, deparaffinization in xylene and vertical sectioning of the root portion with a thickness of 4 μm .

Experiments 3 and 4: A series of horizontal 5- μm thick sections was produced for the PDL region of the roots in question and immune histochemically examined.

3. Histopathology

Specimens were stained with hematoxylin and eosin and were examined under the light microscope.

3.1. Histopathological examination: vertical sectioning of the root portion

Experiment 1: Dense amount of PDL fibroblasts and spindle cells were seen in the control group. Capillaries were congested with red blood cells. PDL fibers were irregularly arranged (**Figure 2A**). At alveolar bone, osteoclasts were noticeable. The furcation is lined by acellular

cementum. First a histopathology view of an experimental group is described. At day 1, capillaries shevel hyperemia were filled with red blood cells dilated. At day 4, hyperemia was observed stronger than day 1. The amount of deeply stained cells with round shape nuclei increased (**Figure 2B**). A lot of osteoclasts were observed on the glassy surface of the alveolar bone. At day 7, the cytological density reduced compared to day 4. Further, osteoclasts appeared in between fibroblasts (**Figure 2C**). Howship's lacunae formed in borders of resorbed alveolus bone and cementum (**Figure 2D**). Resorption of cementum was part of the acellular cementum. At day 14, bone resorption and osteoclasts in lacunae have become more evident as compared to day 7, and resorbed cementum also increased. The PDL at the furcation area in the control group runs in an orderly fashion from the tooth to the alveolar bone. But, the fibroblasts were sort of irregular. It can be speculated that the occlusal force to the furcation was in an equilibrium state.

It was inferred that congestion and vasodilation occurred from day 1. Since there was an increase in hyperemia at day 4, excessive occlusal load caused tissue reaction by a rise in blood supply. But, the blood vessels did not show any change at day 7, and this is considered to be affected by the HSP47. On the other hand, the osteoclasts in Howship's lacunae as well as bone resorption continued to rise. The osteoclasts expressed by occlusal trauma have been derived from bone marrow [13]. According to this result, the osteoclasts observed at day 7 were probably bone marrow derived cells. The enlargement of Howship's lacunae at day 14 compared to day 7 suggested that the activity of the osteoclasts was elicited excessive load.

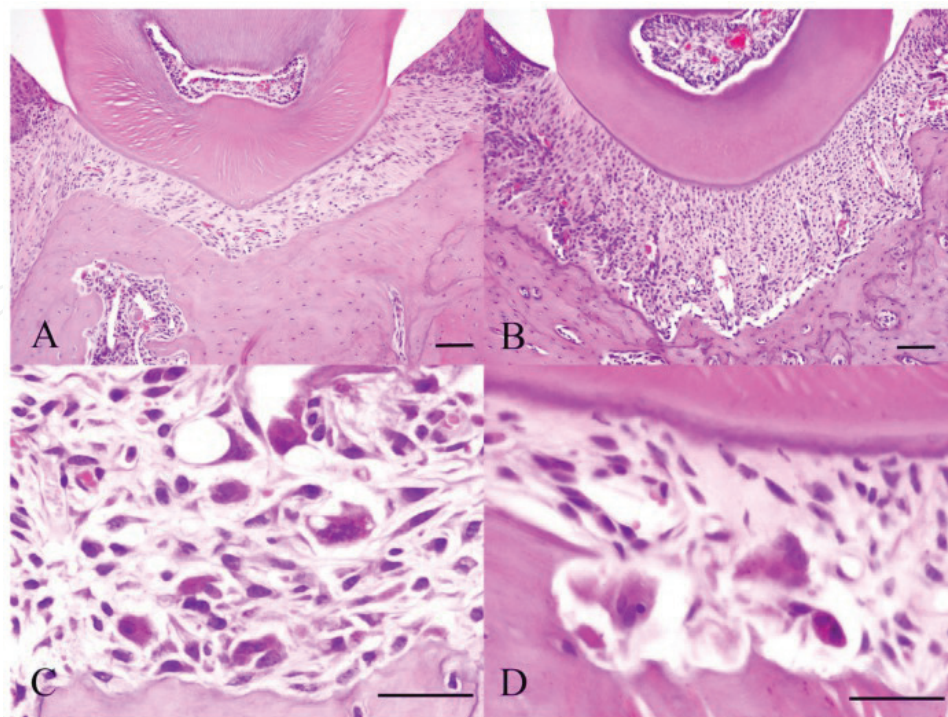


Figure 2. Histopathology of Experiment 1. Control specimen (A), Experimental day 4 specimen (B), Experimental day 7 specimen (C) and Experimental day 14 specimen (D). The inset scale bar indicates 50 μm . Quotation alteration of literatures #14.

Experiment 2: In the control group, strong hyperemia was seen at day 4 (Experimental group 1). At day 3 of the experimental group, significant vasodilation were observed compared to control group. Osteoclasts were scattered in the alveolar bone and some formed clusters in Howship's lacunae (**Figure 3A**). At day 6, capillaries were decreased in hyperemia, and fewer osteoclasts were noted. Fibroblasts were deeply stained with hematoxylin stain and have round shape nucleus. At day 10 of the experimental group, Howship's lacunae were more observed compared to day 6. Fibroblasts and dilating capillaries were no longer conspicuous at day 30. These histological findings at day 30 of the experimental group are similar to the control group in experiment 1 (**Figure 3B**).

To summarize this finding, at the experimental group of day 3, hyperemia was not so prominent compared to control group, and when occlusal overload was released, hyperemia declined as well. At day 6 and 10, osteoclasts were reduced. The osteoclasts were induced by the implantation of micro screw at day 4, and these activities continued even if the micro screw was removed.

Howship's lacunae were enlarged at day 10 compared to day 6. The constant activity of osteoclasts was brought about by the influence of occlusal overload which allowed the cells to proceed to the activity which already began. This result means that osteoclasts was increased due to occlusal overload and continued to increase even when the occlusal overload was removed. The congestion or vasodilation was no longer observed at day 30 of the experiment. It can be inferred that the periodontal ligament was restored to its equilibrium state at day 30 of the experimental group.

3.2. Histopathological examination: horizontal sectioning of the root portion

Experiment 3: The distal buccal root of the upper jaw first molar was horizontally examined. At the control group, the mesial side of root had a slight deviation where the PDL width is about 50 μm . The distal side of PDL in between the alveolar bone and the distal buccal root of the left maxillary first molar were relatively arranged in order (**Figure 4, C-H, C-T**). In contrast, the mesial side PDL of the distal buccal root and the PDL fibroblasts were observed in a diagonal orientation (**Figure 4, C-P**).

At the experimental group, the PDL located near by the separator were called the tension side (PDL of the distal side at the distal buccal root of right maxillary first molar); the PDL located

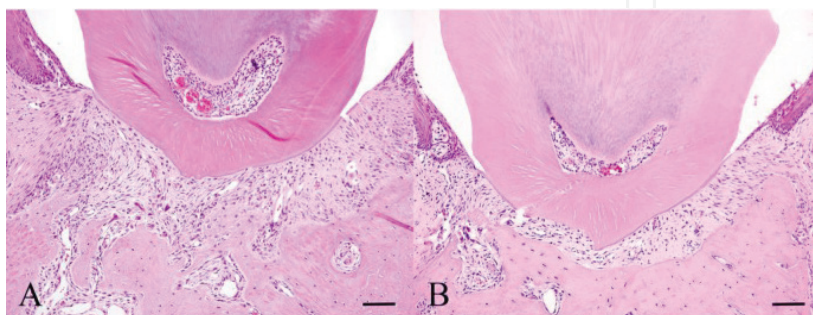


Figure 3. Histopathology of Experiment 2. Experimental day 3 specimen (A) and Experimental day 30 specimen (B). The inset scale bar indicates 50 μm . Quotation alteration of literatures #14.

at opposite side were called the pressure side (PDL of the mesial side PDL at the distal buccal root of the maxillary first molar). The 20 min group of the tension side, difference between the tension and pressure side became apparent (**Figure 4**, 20m-H, 20m-T, 20m-P). 1 h group

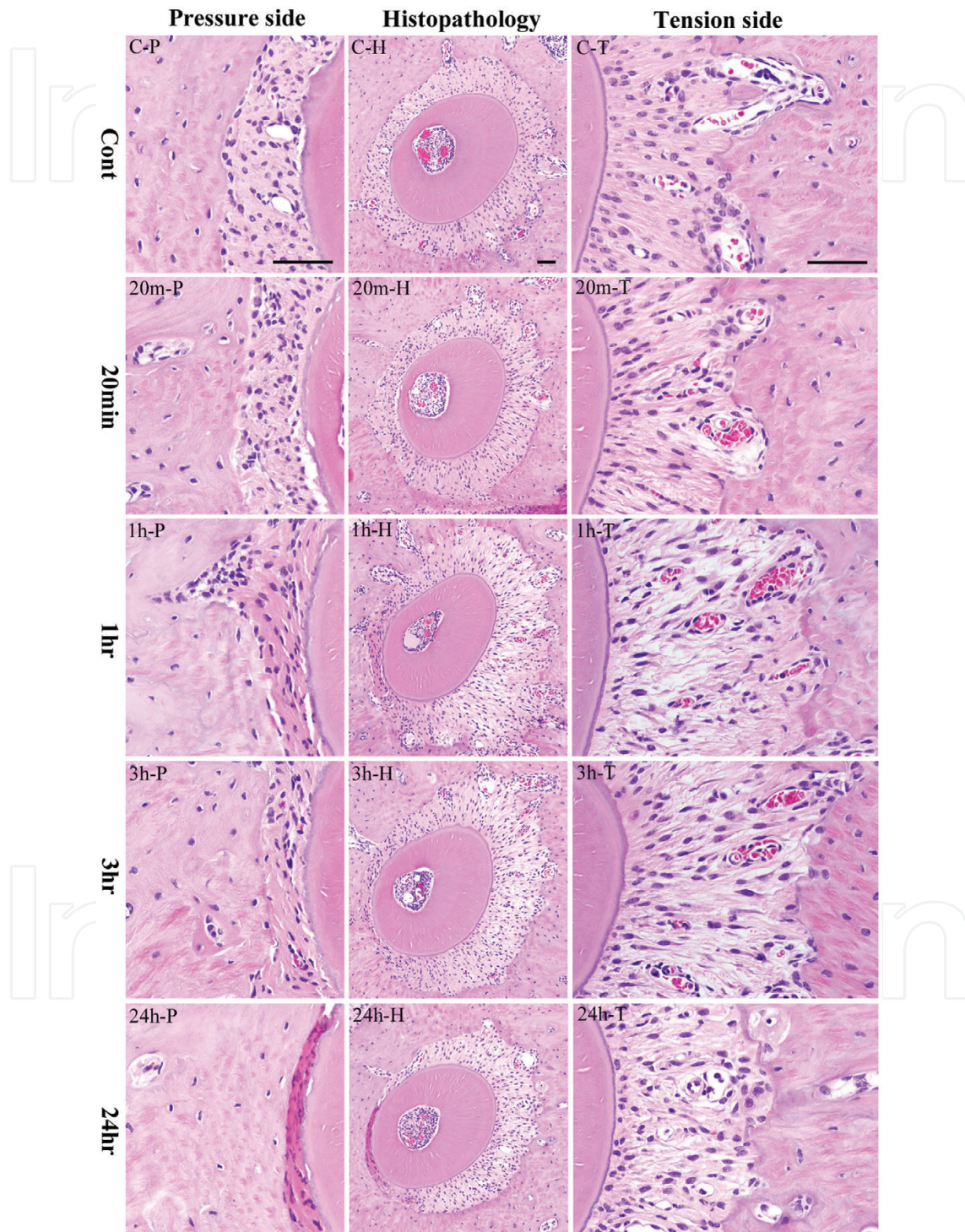


Figure 4. Histopathology of Experiment 3. Center histopathological image shows the alveolar bone socket morphology. Left and right histopathological image shows high power view of pressure side and tension side. The most upper row is the control group (cont), and the following is the experimental groups of 20 min (20 min), 1 h (1 h), 3 h (3 h) and 24 h (24 h). The inset scale bar indicates 50 μ m. Quotation alteration of literatures #2.

of the tension side, the root moved further to the mesial direction (**Figure 4**, 1h-H). The PDL width created a greater traction and the fibers had been stretched considerably (**Figure 4**, 1h-T). The 1 h group of the pressure side, the PDL cells showed various degenerative changes. Furthermore, osteoblasts lining the bone surface were reduced in number; the cytoplasm and nucleus became flattened by pressure and distinction among surrounding fibroblasts became difficult (**Figure 4**, 1h-P). The 3 h group of the tension side, the root continued to move mesially and the width of the PDL space increased (**Figure 4**, 3h-H). The number of fibroblasts decreased compared to the 1 h group. Oval-shaped osteoblasts are observed lining the surface of the alveolar bone (**Figure 4**, 3h-T). The 3 h group of the pressure side, the PDL space further became narrower; degenerative changes were more severe that distinction of PDL cells was difficult. PDL fibroblasts increased its eosinophilic staining; they had fewer nuclei per unit area. Osteoblasts lining bone surfaces were also fewer (**Figure 4**, 3h-P). The 9 h group of the tension side, the root stopped moving in the mesial direction and the width of the PDL did not further increase. The gap in between collagen bundles was reduced. The 9 h group of the pressure side, eosinophilic staining of the PDL further increased; the number of PDL fibroblasts decreased. Moreover, some obscure spaces partly in the fiber bundles showed hematoxylin staining caused by karyolysis. The 24 h group of the tension side, osteoblasts lining the alveolar bone surface are oval or short cuboidal in shape. Dilated vessels and scattered hemorrhages can be observed (**Figure 4**, 24h-H, 24h-T). The 24 h group of the pressure side, the PDL became strongly eosinophilic. Strong nuclear chromatin condensation or pyknosis has been observed in PDL fibroblasts, karyorrhexis is very evident (**Figure 4**, 24h-P).

4. Immunohistochemistry

Experiments 1 and 2: This was followed by embedding in paraffin, deparaffinization in xylene and vertical sectioning of the root portion with a thickness of 4 μm . After deparaffinization, the slides were treated in incubator at 60°C for 30 min. Specimens were subjected to proteolytic enzyme, immersed in 0.03% hydrogen peroxide methanol solution for 3 min, followed by endogenous peroxidase activation for 10 min. Anti-HSP47 was the primary antibody (1/2000 dilution). Polyclonal anti-rabbit was the secondary antibody [14]. Then after, slides were washed with PBS and then subjected to DAB color development for 3 min. Finally, counterstaining was done by immersing the specimen in hematoxylin for 1 s.

Experiments 3 and 4: A series of horizontal 5- μm thick sections was produced for the PDL region of the roots in question and immune histochemically examined. The immunohistological study was carried out using Dako Envision+Kit. Anti-rabbit HSP47 polyclonal antibody was the primary antibody (1/1000 dilution) [1]. The specimens were counterstained with hematoxylin. The negative controls were treated by using the same experimental protocol, but without the primary antibody.

4.1. Immunohistochemical examination: vertical sectioning of the root portion

Experiment 1: HSP47 was slightly detected in the cytoplasm of fibroblasts in the control group (**Figure 5A**). Other cells that were scattered in the periodontal ligament were also positive to

HSP47 (**Figure 5B**). At day 1, HSP47 expression was detected more in fibroblasts in epithelial attachment, the intensity was similar to those in the control group. At day 4, HSP47 was detected in the entire periodontal ligament. Strong expression was detected in the fibroblast with which covered an alveolar bone in particular (**Figure 5C**). More expression of HSP47 was increased on day 7 more than day 4. HSP47 was also detected by a vascular endothelial cell. The strongest expression of HSP47 was detected by a cell of fibroblasts on day 14 (**Figure 5D**).

In the control group, periodontal ligaments expressed HSP47 even though they were at equilibrium. Only few cells in junctional epithelium and subepithelial connective tissue showed positive reaction. This result means that HSP47 was co-expressed at cells of nonstress condition in which the protein was regulated at the transcription level. Moreover, we mentioned that the weak expression of HSP47 [5, 6] in normal tissues was considered to be involved in the maintenance of homeostasis in the periodontal tissue. From day 1, fibroblasts near the epithelial attachment expressed HSP47. The findings were similar to our study of horizontal sectioning of the root portion where HSP70 was initially detected on tension side of PDL after loading orthodontic force. This result suggests that HSP47 is initially involved in remodeling of collagen fibers on tension side upon mechanical stress application. HSP47 was increased at a cell on the alveolar bone in particular on day 4. Compression of a PDL was clear because a collagen fiber received restoration. HSP47 has begun to show conspicuously in an endothelial cell on day 7. This suggests that becoming a capillary depends on surplus occlusal load. Although there was no increase in congestion at day 4, but HSP47 was still considered to be involved in the process. HSP47 had peaked on day 14 and kept being increased by a continuous load. You can guess the collagen fibers to keep restoring under the existence of a

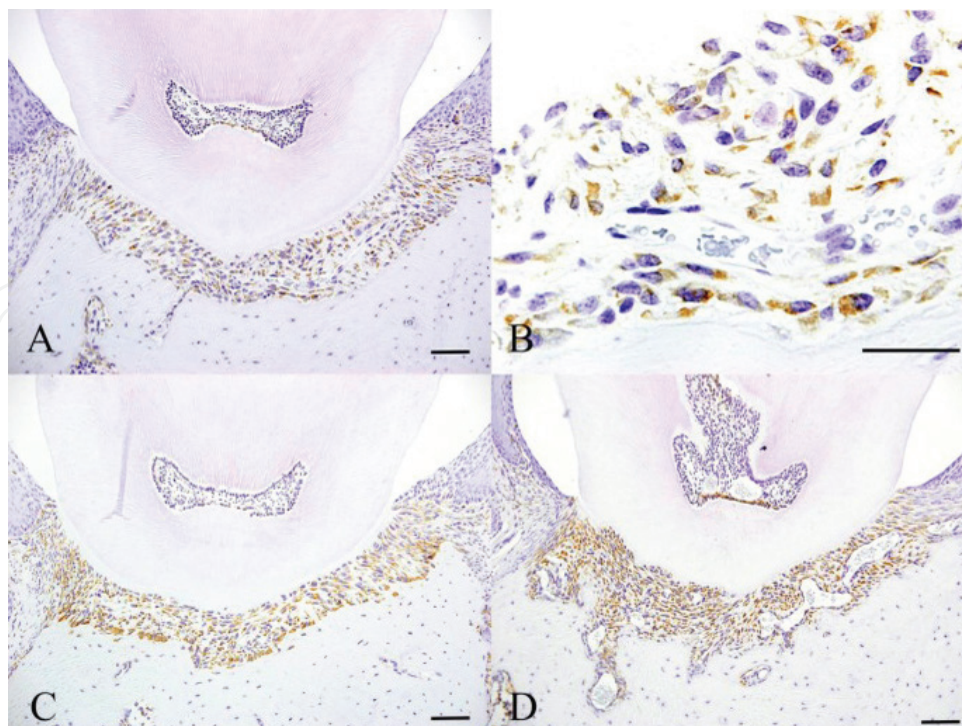


Figure 5. Immunohistochemical features of Experiment 1. Control specimen (A, B), Experimental day 4 specimen (C) and Experimental day 14 specimen (D). The inset scale bar indicates 50 μ m. Quotation alteration of literatures #14.

traumatic occlusion. Fibrosis follows a continuous stress by successive accumulation of a collagen fiber. These suggest that manifestation of HSP47 always participated in a physiological remodeling of a periodontal ligament by the excessive occlusal load.

Experiment 2: At day 3, the number of fibroblasts that expressed HSP47 was similar to the control group (**Figure 6A**). Some cells scattered in the periodontal ligament also expressed HSP47. The manifested strength on day 6 was increased more than day 3 (**Figure 6B**). Most of a positive cell possesses round nuclei. At day 10, the number of the cell which indicates positive reaction decreased more than the sixth day (**Figure 6C**). A small number of scattered cells were positive and this was equal to opposition on day 30 (**Figure 6D**). On day 3, HSP47 was slightly stronger than the control group suggesting the progressive repair of damaged collagen.

Though excessive occlusal load was removed, the cell with which I cover an alveolar bone kept manifesting expressions of HSP47 on day 4. HSP47 kept being increased on day 6 and decreased on day 10. Thus, HSP47 tends to be increased with the over time. But on day 30, the expression of HSP47 was like the contrasting group and that a cell had returned to equilibrium state. The previous studies had shown the increase in HSP expression caused by mechanical stress and decrease upon mechanical load release. Our data suggested that HSP47 expressed by damaged epidermis during wound healing, and damaged cells caused by mechanical trauma also express HSP47 [23]. Continuous expression of HSP47 prevented a disturbance of epidermal cells, abnormal cell division, rupture of a blood vessel and other

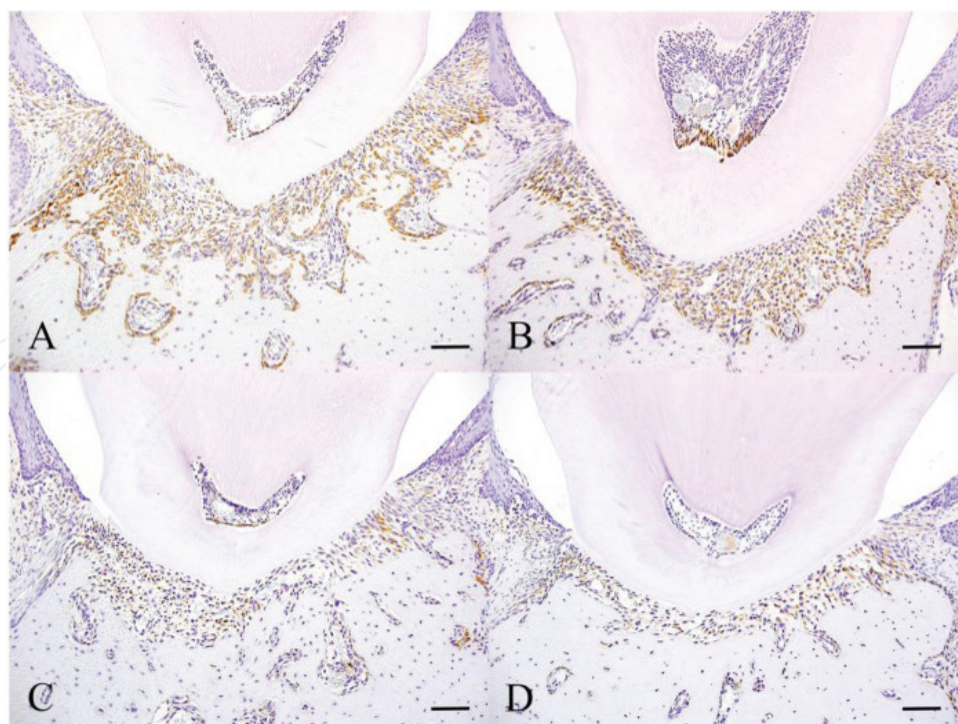


Figure 6. Immunohistochemical features of Experiment 2. Experimental day 3 specimen (A), Experimental day 6 specimen (B), Experimental day 10 specimen (C) and Experimental day 30 specimen. The inset scale bar indicates 50 μm . Quotation alteration of literatures #14.

occurrence of apoptosis. The continuous HSP expression from day 1 to the day 14 was a defending reply. The abnormal function of HSP47 was observed by the collagen bundles of the periodontitis damaged.

4.2. Immunohistochemical examination: horizontal sectioning of the root portion

Experiment 3: In the PDL tissue from mouse in the control group, HSP47 expression was detected in the cell cytoplasm of the PDL collagen bundles uniformly over the entire PDL (**Figure 7**).

In the PDL tissue from mouse in the experimental group, the distal side of the PDL on the side in which the separator was inserted was the tension side and the proximal PDL on the opposite side was the pressure side. After loading mechanical stress over time up to 24 h by inserting a separator, histological analysis of the mouse periodontal tissue was performed (**Figure 8**).

In the 10 and 20 min group, there was hardly any clear difference in the intensity of HSP47 expression when compared with the control group. There was a clear difference in the width of the PDL on the tension side and PDL on the pressure side by a 1 h group. HSP47 manifestation in expansion PDL on the tension side was stronger than HSP47 manifestation in opposition. PDL space on the pressure side shrunk and was small by a 3 h group, and the width of the PDL space on the side pulled it and expanded more, and PDL fiber in this territory was extended conspicuously. PDL fiber was sparsely by the part of PDL, and there was a place where PDL fiber breaks and causes space. But the manifestation of HSP47 on the tension side was stronger than that of the control group. The expansion width of tension side PDL observed by a 3 h group was maintained by a 9 h group. However, the intensity of HSP47 expression showed localized changes in the 9 h group. Stronger HSP47 manifestation was observed on the pressure side more than the tension side. A stronger HSP47 reply was observed in PDL on the tension side by a 24 h group. However, on the pressure side, HSP47 expression disappeared because the PDL fibroblasts were strongly compressed, but HSP47 expression was detected in the PDL fibroblasts adjoining the compressed PDL.

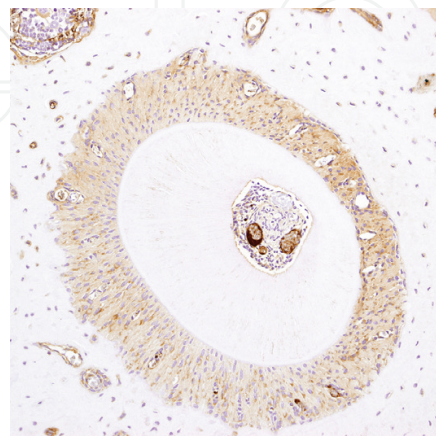


Figure 7. Immunohistochemical results of the control group. IHC staining profile of HSP47 in control specimens. The inset scale bar indicates 50 μm . Quotation alteration of literatures #1.

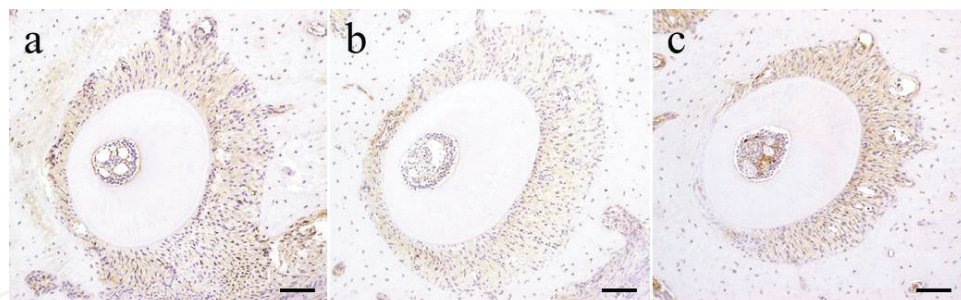


Figure 8. Immunohistochemical results of Experiment 3 at horizontal sectioning of the root portion. (a) 3 h group, (b) 9 h group and (c) 24 h group. The inset scale bar indicates 50 μ m. Quotation alteration of literatures #1.

Summarize the results of immunohistochemical experiment 3. So early time, a positive HSP47 response appeared in the PDL on the tension side, and the same level expression of HSP47 was kept for 9 hours. The 24 hours group indicated the manifested strength of HSP47 the most highest in the all experimental group. A positive immunohistochemistry-like HSP47 response in the tension side indicated strong step-by-step increase with the passage of time. The low manifested position was maintained about immunohistochemistry-like HSP47 positive reaction on the pressure side, and there were no manifested conspicuous changes after stress loaded. But strong positive reaction was detected by a group for 9 hours. A PDL fibroblast was compressed hard by a group for 24 hours, but HSP47 manifestation disappeared on the pressure side because strong HSP47 manifestation was detected in a PDL fibroblast which neighbors compressed PDL. In the 24 hours group, HSP47 expression disappeared in the pressure side because of the PDL fibroblasts were strongly compressed. But intense HSP47 expression was detected in the PDL fibroblasts adjoining the compressed PDL.

Experiment 4: After 3 h of mechanical stress loading, separator was removed. Mouse periodontal tissue of upper jaw was removed for the passage of time until after 1 week. An immunohistochemistry analysis of HSP47 manifestation with the passage of time in the mouse PDL organization of the territory concerned was performed. Just after having removed separator for 3 h + 0 min after impressing mechanical stress for 3 h, a manifested local change in HSP47 was observed at the tension side and the pressure side of mouse PDL. The manifestation of HSP47 in PDL on the tension side was higher than the control group. Manifestation of HSP47 on the pressure side did not change and was while being weak. In the 3 h + 20 min group the intensity of HSP47 expression in the whole around the root of the tooth was also similar to 3 h + 0 min group. The strength of HSP47 manifestation in PDL on the tension side was maintained more than a group in 3 h + 0 min and 3 h + 20 min by a group for 3 + 1 h. Manifestation of HSP47 was increased in PDL on the pressure side, and there was not a clear difference between the pressure side and the tension side in the strength of HSP47 manifestation. HSP47 manifestation was similar on both sides. The location of the root of the alveolar socket returned to an initial position substantially by a group for 3 + 3 h, and the width of PDL was convalescent. HSP47 manifestation in the pressure side and the tension side was increased more than that of a group for 3 + 1 h. HSP47 manifestation in PDL on the pressure side was stronger than something which can be put in PDL on the tension side. There were no changes in HSP47 manifestation by a group for 3 + 9 h. However, 24 h after removing separator (3 + 24 h), HSP47 expression was again noticeably increased over the entire PDL. A positive HSP47 response was also noted in the osteoblasts and the bone cells of

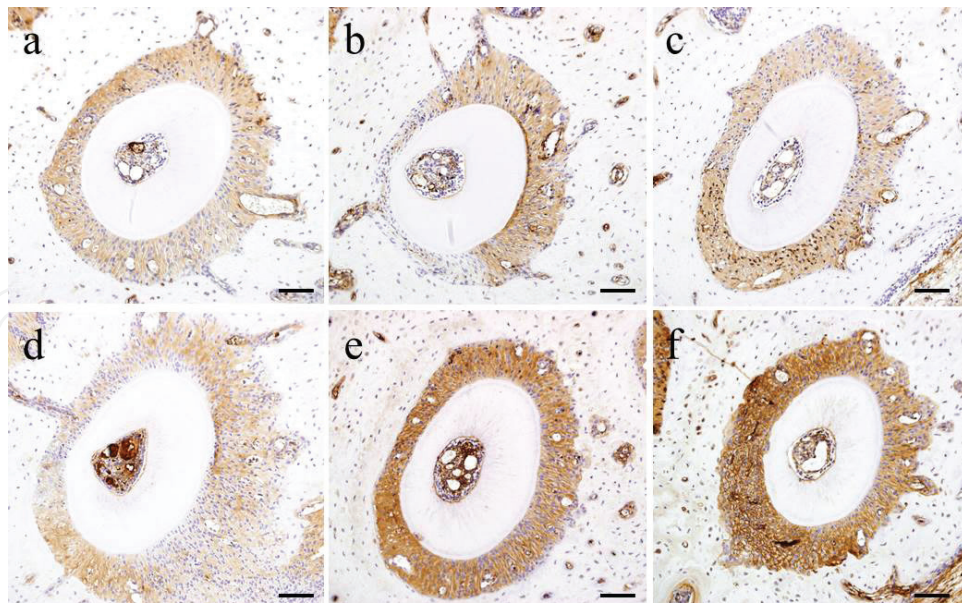


Figure 9. Immunohistochemical results of Experiment 4. (a) Control group, (b) 3 h + 0 min group, (c) 3 + 3 h group, (d) 3 + 9 h group, (e) 3 + 24 h group and (f) 3 h + 1 w group. The inset scale bar indicates 50 μ m. Quotation alteration of literature #1.

the alveolar bone. The same response was also observed 3 days after remove separator (3 h + 3 d). HSP47 expression remained strong over the entire PDL 1 week after remove separator (3 h + 1 w). However, expression of HSP47 was weaker than 24 h after release separator.

Summarize the immunohistochemical experiment 4. So early, a positive HSP47 response appeared in the PDL on the tension side, and the same level expression of HSP47 was kept for 9 h. The 24 h group indicated the manifested strength of HSP47 the most highest in all experimental groups. A positive immunohistochemistry-like HSP47 response on the tension side indicated strong step-by-step increase with the passage of time. The low-manifested position was maintained about immunohistochemistry-like HSP47 positive reaction on the pressure side, and there were no manifested conspicuous changes after stress loaded. But a strong positive reaction was detected by a group for 9 h. A PDL fibroblast was compressed hard by a group for 24 h, but HSP47 manifestation disappeared on the pressure side because strong HSP47 manifestation was detected in a PDL fibroblast which neighbors compressed PDL (**Figure 9**).

5. Discussion

Long-term excessive occlusal force and occlusal trauma has an influence on the PDL. An occlusal trauma has a destructive influence on a periodontal tissue [24–27]. It has been studied variously about a relation between a traumatic occlusion and bone resorption. Glickman et al. [28] reported that an inflammatory change is caused by pathogenicity bacteria in a serious periodontitis syndrome with a progressive bone resorption, but influence by both of the excessive occlusal force and occlusal trauma. They were experimented with the rat to which the excessive occlusal load has been added by Kaku et al. [29]. It was transplanted to the upper jaw first molar for micro plus screw with average head diameters to generate

high occlusal contact uniformly in that experiment. It was possible to reduce the torque by tightening micro plus screw cross recessed up during the experimental period. The too early contact which makes a molar cause the excessive occlusal load was also easy to produce because the gliding movement of the jaw of a mouse was easy relatively. A result suggested that increase of a fibroblast as the part of the remodeling of a periodontal tissue depends on adaptation to the excessive occlusal load. We considered that a histology-like change in a fibroblast is increased significantly on day 4 and prepared a different experimental system about this regard. When paraphrasing, the implantation of the micro plus screw to cause a traumatic occlusion was possible by the day 4. So we were examined about that histological and expression of HSP47 after traumatic occlusion. Osteoclast was induced by transplantation of a micro plus screw on day 4, and even if a micro plus screw was removed, the way continued. On the other hand, a fixed way of an osteoclast was brought by influence of occlusal overload, and it was possible to advance toward the activity that a cell has already been begun by that. This was indicated by expansion of a glandular cavity of Howship's on day 10 more than day 6. Increase of an osteoclast depends on occlusal overload, and even if a load is removed, this means that it kept being increased. Becoming or a hemangiectasis with the histology-like features like the contrasting group was no longer observed on day 30. It is possible to guess a root of the periodontal ligament to have been convalescent in equilibrium state on day 30.

In summary of experiment about the vertical sectioning of the root portion, there is a possibility that a collagen fiber in a periodontal ligament is destroyed for a continuous occlusal overload. This was clear by increase of HSP47 expression by arrangement of a micro plus screw. HSP47 is maintained by a fibroblast for restoration of the damaged collagen fibers. Simultaneously, though a load to stress was released, an osteoclast keeps being increased. The osteoclast which appeared on the alveolar bone surface is probably caused by sustained activity and it is activated. We presumed increase of an osteoclast to happen after load application on day 4. It kept being increased until day 6 of experimental 2, but HSP47 decreased on day 10. Therefore, HSP47 shows after a period of certain activities that a damaged collagen fiber is restored. The activity of HSP47 returned to equilibrium state on day 30, and expression of HSP47 decreased significantly.

We focused on the collagen fiber which is a main component of a PDL and check manifested movement of HSP47 which is peculiar molecular chaperone in the collagen. HSP localized in the endoplasmic reticulum in the fibroblasts of the PDL.

Heat-shock protein is one kind of proteins by which manifestation is reinforced with a stress [16]. HSP is the stress protein caused by an inflammation, a physical stress, a chemical stress and a pathological change in a heat shock. A stress response functions as the universal and basic defense mechanism which participates in a biological defense response. HSP was the protein from which even the state that has no stress ranges to a cell of equilibrium state widely, and it was indicated clearly by in vitro and in vivo experiment that HSP is the indispensable protein to various cellular function of a cell differentiation, multiplication, survival and maintenance of function [17, 30, 31]. HSP are polypeptides which are classified by molecular weight, and each has different functions. Many HSPs suppress protein modifications as well as repair of modified proteins. They are molecular chaperones [30]

having a so-called anti-apoptosis function to escape cell death [17, 18]. Periodontal ligament is the fibrous connective tissue which is surrounding the dental root. A tooth is fixed on an alveolar bone and mechanical stress of the occlusal pressure is received periodically. The biological metabolic half-life of PDL is very short in 1 day. PDL is composed of much cell type like a fibroblast, an osteoblast, an epithelium stationary stem cell of an osteoclast, a cementoblast, cementoclasts and Malassez, a mastocyte and a macrophage. A blood vessel, a nerve and a matrix protein outside the collagen fibers and the cell of an oxytalan fiber and a sugar protein exist. The type I collagen is the main ingredient (90%) about an ingredient of a periodontal film, there is less type III collagen (10%), and type V collagen is present in very small quantities. The collagen is one of general fibrous proteins most at the interior of the body of an animal. The collagen is formed to construct more than one numerator out of in vivo. A polypeptide of the amino acid 1000 combined is included in the collagen molecule of which the unit of the collagen is composed. Three α chains form a spiral and form the collagen fibers.

HSP47 defends a cell against a stress and supports maturity of the collagen in the cell and secretion. When normal synthesis is failed for a stress of the different type, and abnormality has occurred to the collagen structure; HSP47 obstructs a cell external secretion of the abnormal collagen and stores a modified protein in an endoplasmic reticulum. It was reported that indispensable molecular chaperone is HSP47 to form the collagen with the right three chains reported by Nagata et al. [32, 33] in 1986. Abnormality occurs to formation of a collagen fiber including the type I collagen by a collagen-specific molecular chaperone HSP47 lost knockout mouse. Abnormality is admitted by basic film formation with abnormality of the type IV collagen, and a mouse is embryonal fatality [34, 35]. Therefore, HSP47 is the molecular chaperone indispensable to normal occurrence in a mammal and a histogenesis. Accordingly, it was thought that HSP47 would be similarly expressed in the periodontal ligament in vivo when mechanical stress such as excessive occlusal force or orthodontic force is loaded.

Some researchers did experiments on animals to establish an immunohistological basis for a orthodontic treatment at the past. They were a basic research about a tooth movement of orthodontic treatment and the mechanism in the root in order to clarify aspects of bone absorption and addition and the underlying mechanism which has a clear have long history. After loading the mechanical stress which imitated the orthodontic treatment, we studied the various proteins manifested in a periodontal tissue of a mouse using the experiment that horizontal sectioning of the root portion [1–12]. However, almost no cellular responses related to harmful influential restoration of mechanical stress to a PDL fibroblast during an orthodontic treatment is studied. Therefore, we focused on manifested HSP to oppose various types of cell damage. Expression of HSP peptides occurs within an extremely short time in PDL cells subjected to mechanical stress over time [2, 4–6, 8, 11, 12]. Therefore, we infrared HSP47 which contributes to a cell differentiation was manifested by a short time relatively and that a manifested strong change in HSP47 might be observed within 24 h. The experimental periods of these experiments were set to enable comparison with the data obtained by Watanabe et al. [11, 12] Matsuda et al.[4, 8], and prior reports [2, 5, 6, 9], from 10 min to a maximum time of 24 h after inserting a separator. Moreover, in order to investigate the recovery of the PDL from damage caused by the mechanical stress, after

loading a mechanical stress to the mouse PDL tissue for only 3 h, HSP47 expression was observed over time up to a maximum time of 1 week after releasing the stress. These results show that, in the PDL at the control group (distal buccal root of untreated mouse upper left first molar), HSP47 expression was noted in the cell cytoplasm of the PDL collagen bundles uniformly over the entire periodontal membrane and remained low level. At the normal circumstances, teeth are subjected to mechanical stress caused by mastication several thousand times per day. Under these circumstances, the supporting PDL tissue maintains its physiological functions. These findings in the control group PDL agree with reports that other HSP such as HSP27 and HSP70 are present even in the absence of stress [17, 36, 37] and act to maintain physiological functions in the PDL tissue [2, 5, 6]. It appears that, like these proteins, HSP47 is also expressed in the absence of stress and serves as an element of the mechanism underlying the physiological functions of the PDL tissue and maintains the homeostasis of the PDL.

Next, in the experimental groups subjected to mechanical stress over time for up to 24 h, HSP47 expression was detected in the PDL on the tension side from a very early time and gradually increased over time with the greatest increase in the 24 h group. No marked change was detected in HSP47 expression on the pressure side, after loading stress, expression of HSP47 was maintained low level. However, a strong positive HSP47 response was observed in the 9 h group. However, on the pressure side in the 24 h group, HSP47 expression was absent because the PDL fibroblasts were strongly compressed, but intense HSP47 expression was detected in PDL fibroblasts adjoining the compressed PDL. When examining the time course of HSP47 expression after loading a mechanical stress, HSP47 expression occurred with the same timing as the expression of proteins such as Runx2, Msx2, ALP, BMP, Smad and P-Smad reported by Watanabe et al. and Matsuda et al., which contribute to controlling bone formation by activating osteoblasts [4, 8, 11, 12]. These data suggest that during addition of a bone to PDL on the tension side. HSP47 also has a molecular chaperone function, assisting the maturation of bone morphogenetic proteins and supporting osteoblast activation.

Further, we observed expression of HSP47 at different time points after loading a mechanical stress to the mouse PDL tissue for only 3 h and releasing the stress up to at most 1 week. HSP47 was manifested highly in PDL on the tense side at the very early stage of the later when mechanical stress was freed, but manifestation in a periodontal film on the pressure side was while being still weak. However as time passed, the width of the compressed PDL was gone back in the previous early stage width before applying stress, and HSP47 expression in the PDL on the pressure side increased, and 3 h after release, when the position of the root in the alveolar bone had almost returned to the initial state, HSP47 expression was stronger in the periodontal membrane on the pressure side than that in the periodontal membrane on the tension side. After 24 h releasing the stress, expression of HSP47 notably increased over the entire PDL, and expression of HSP47 remained at a high level over the entire PDL until 1 week after release the stress. These reactions are thought to have been caused by the mechanical stress on the PDL. We previously reported that HSP70, expressed on a pressure side, which has been subjected to intense cell damage, may contribute to osteoclast differentiation on the pressure side, suppresses modification of nascent protein therein and fulfills the function of carrying

out management and repair of modified proteins, which cannot be regenerated [6]. It is conjectured that HSP47 which, like HSP70, has a function in tissue repair, is expressed in PDL fibroblasts on the pressure side damaged by applying a mechanical stress, contributes to repairing collagen tissue by activating PDL fibroblasts and contributes to the recovery from cell damage. Moreover, as previously mentioned, HSP47 manifested by the fibroblasts on the tension side probably has a molecular chaperone function, which assists the maturation of bone morphogenetic proteins and aids osteoblast activation. However, when mechanical stress is loaded to the PDL on the tension side during time which is not enough for bone addition, cell damage forms, and there is a possibility that abnormality occurs to the collagen structure of the PDL fibroblast. By functioning at the damage site, HSP47 obstructs a cell external secretion of the abnormal collagen, stores a modification protein in an endoplasmic reticulum and controls decalcification which is the feature of PDL by that by functioning by a damage part.

6. Conclusions

The results suggest that HSP47 is actively involved in homeostasis of periodontal tissue subjected to mechanical stress and occlusal overload. In other words, HSP47 is constitutively expressed in the PDL and defends cells from different types of stress and maintains homeostasis under normal conditions.

There is a possibility that a collagen fiber in the PDL is destroyed for mechanical stress and a continuous occlusal overload. HSP47 is manifested in the PDL fibroblast damaged by application of mechanical stress. HSP47 contributes to restoration of the collagen organization by activating a PDL fibroblast and supports a recovery from cell damage.

HSP47 was suggested that in the course of the alveolar bone addition to the PDL at the tension side, that also acts as molecular chaperone and that support the maturation of bone morphogenetic proteins and aids osteoblast activation.

Further, HSP47 inhibits extracellular secretion of abnormal collagen, stores the modified protein in the endoplasmic reticulum, thereby controlling decalcification of the PDL.

HSP47 acts differently depending on the time of expression in PDL.

Acknowledgements

This research was partially supported in part by JSPS KAKENHI Grant Numbers 23792456, 26861804, 26463104 and 25463204 from the Japan Society for the Promotion of Science (JSPS).

Conflict of interest

The authors have declared no COI exists.

Author details

Rina Muraoka^{1*}, Keisuke Nakano², Hidetsugu Tsujigiwa³, Hitoshi Nagatsuka², Hirokazu Matsuda¹, Mihoko Tomida^{1,4}, Norimasa Okafuji^{1,4}, Kazuhiro Yamada^{1,4} and Toshiyuki Kawakami⁴

*Address all correspondence to: rina.muraoka@mdu.ac.jp

1 Matsumoto Dental University School of Dentistry and Hospital, Shiojiri, Japan

2 Okayama University Graduate School of Medicine, Dentistry and Pharmaceutical Sciences, Okayama, Japan

3 Faculty of Science, Okayama University of Science, Okayama, Japan

4 Matsumoto Dental University Graduate School of Oral Medicine, Shiojiri, Japan

References

- [1] Muraoka R, Nakano K, Yamada K, Kawakami T. HSP47 as a possible molecular chaperone for the collagen synthesis in the mouse periodontal ligament cells due to orthodontic force. *International Journal of Dentistry and Oral Science*. 2017;4(1):387-394. DOI: 10.19070/2377-8075-1700078
- [2] Muraoka R, Nakano K, Kurihara S, Yamada K, Kawakami T. Immunohistochemical expression of heat shock proteins in the mouse periodontal tissues due to orthodontic mechanical stress. *European Journal of Medical Research*. 2010;15(11):475-482
- [3] Kawakami T, Nakano K, Shimizu T, Kimura A, Okafuji N, Tsujigiwa H, Hasegawa H, Nagatsuka H. Histopathological and immunohistochemical background of orthodontic treatment. *International Journal of Medical and Biological Frontiers*. 2009;15(7/8):591-615
- [4] Matsuda H, Muraoka R, Tomoda M, Nakano K, Okafuji N, Yamada K, Kawakami T. Immunohistochemical observation of BMP in the mouse orthodontic periodontal tension sides. *Journal of Hard Tissue Biology*. 2009;18(4):181-184
- [5] Muraoka R, Nakano K, Matsuda H, Tomoda M, Okafuji N, Kurihara S, Yamada K, Kawakami T. Immunohistochemical observation of heat shock proteins expression in mouse periodontal tissues due to orthodontic mechanical stress. *Journal of Hard Tissue Biology*. 2009;18(4):193-197
- [6] Muraoka R, Nakano K, Matsuda H, Tomoda M, Okafuji N, Yamada K, Kawakami T. A consideration on the role of HSP70 appearing in the periodontal tissues due to experimental orthodontic force. *Journal of Hard Tissue Biology*. 2011;20(4):275-282
- [7] Muraoka R, Tsujigiwa H, Nakano K, Katase N, Tamamura R, Tomida M, Okafuji N, Nagatsuka H, Kawakami T. Transplanted bone marrow-derived cell migration into periodontal tissues and cell differentiation. *Journal of Hard Tissue Biology*. 2011;20(4):301-306
- [8] Matsuda H, Harada T, Muraoka R, Tomoda M, Okafuji N. Immunohistochemical observation of osterix appearing in the mouse orthodontic periodontal tissues. *Journal of Hard Tissue Biology*. 2011;20(4):283-288

- [9] Tomoda M, Nakano K, Muraoka R, Matsuda H, Yamada K, Kawakami T. Immunohistochemical changes of heat shock protein 27 expression in the mouse periodontal tissues exposed to orthodontic mechanical stress. *Journal of Hard Tissue Biology*. 2012; **21**(1):43-50
- [10] Tomida M, Tsujigiwa H, Nakano K, Muraoka R, Nakamura T, Okafuji N, Nagatsuka H, Kawakami T. Promotion of transplanted bone marrow-derived cell migration into the periodontal tissues due to orthodontic mechanical stress. *International Journal of Medical Sciences*. 2013; **10**(10):1321-1326
- [11] Watanabe T, Nakano K, Muraoka R, Shimizu T, Okafuji N, Kurihara S, Yamada K, Kawakami T. Role of Msx2 as a promoting factor for Runx2 at the periodontal tension sides elicited by mechanical stress. *European Journal of Medical Research*. 2008; **13**:425-431
- [12] Watanabe T, Okafuji N, Nakano K, Shimizu T, Muraoka R, Kurihara S, Yamada K, Kawakami T. Periodontal tissue reaction to mechanical stress in mouse. *Journal of Hard Tissue Biology*. 2007; **16**:71-74
- [13] Takaya T, Mimura H, Matsuda S, Nakano K, Tsujigiwa H, Tomita M, Okafuji N, Fujii T, Kawakami T. Cytological kinetics of periodontal ligament in an experimental occlusal trauma model. *International Journal of Medical Sciences*. 2015; **12**:544-551
- [14] Mimura H, Takaya T, Matsuda S, Nakano K, Muraoka R, Tomida M, Okafuji N, Fujii T, Kawakami T. Functional role of HSP47 in the periodontal ligament subjected to occlusal overload in mice. *International Journal of Medical Sciences*. 2016; **13**:248-254. DOI: 10.7150/ijms.14129
- [15] Ritossa F. A new puffing pattern induced by temperature shock and DNP in drosophila. *Cellular and Molecular Life Sciences*. 1962; **18**:571-573
- [16] Milton JS. Heat shock proteins. *The Journal of Biological Chemistry*. 1990; **265**:12111-12114
- [17] Lindquist S, Craig EA. The heat-shock proteins. *Annual Review of Genetics*. 1988; **22**: 631-677
- [18] Arrigo AP, Landry J. Expression and function of the low molecular weight heat shock proteins. In: Morimoto RI, Tissières A, Georgopoulos C, editors. *The Biology of Heat Shock Proteins and Molecular Chaperones*. North America: Cold Spring Harbor Laboratory Press; 1994. pp. 335-373
- [19] Pan H, Halper J. Regulation of heat shock protein 47 and type I procollagen expression in avian tendon cells. *Cell and Tissue Research*. 2003; **311**:373-382
- [20] Merryman WD, Youn I, Lukoff HD, Krueger PM, Guilak F, Hopkins RA, Sacks MS. Correlation between heart valve interstitial cell stiffness and transvalvular pressure: Implications for collagen biosynthesis. *American Journal of Physiology. Heart and Circulatory Physiology*. 2006; **290**:H224-H231
- [21] Oguro A1, Sakurai T, Okuno M, Nagata K, Atomi Y. The change of HSP47, collagen specific molecular chaperone, expression in rat skeletal muscle may regulate collagen production with gravitational conditions. *Biological Sciences in Space*. 2004; **18**:150-151
- [22] Waldo CM. Method for the study of tissue response to tooth movement. *Journal of Dental Research*. 1953; **32**:690-691

- [23] Keagle JN, Welch WJ, Young DM. Expression of heat shock proteins in a linear rodent wound. *Wound Repair and Regeneration*. 2001;**9**:378-385
- [24] Svanberg G. Influence of trauma from occlusion on the periodontium of dog with normal or inflamed gingivae. *Odontologisk Revy*. 1976;**25**:165-178
- [25] Stahl SS. Accommodation of the periodontium to occlusal trauma and inflammatory periodontal disease. *Dental Clinics of North America*. 1975;**19**:531-542
- [26] Lindhe J, Ericsson I. The influence of trauma from occlusion on reduced but healthy periodontal tissues in dogs. *Journal of Clinical Periodontology*. 1976;**3**:110-122
- [27] Biancu S, Ericsson I, Lindhe J. Periodontal ligament tissue reactions to trauma and gingival inflammation. An experimental study in the beagle dog. *Journal of Clinical Periodontology*. 1995;**22**:772-779
- [28] Glickman I, Smulow JB. Effect of excessive occlusal forces upon the pathway of gingival inflammation in humans. *Journal of Periodontology*. 1965;**36**:141-147
- [29] Kaku M, Uoshima K, Yamashita Y, Miura H. Investigation of periodontal ligament reaction upon excessive occlusal load-osteopontin induction among periodontalligament. *Journal of Periodontal Research*. 2005;**40**:59-66
- [30] Hratl FU. Molecular chaperone in cellular protein folding. *Nature*. 1996;**381**:571-579
- [31] Sakurai Y, Okuyama N, Tamamura K, Owawa R, Ito H, Yamasaki A. Expression of collagen-specific stress protein Hsp47 in rat epithelial tissue. *Ohu University Dental Journal*. 2007;**34**(4):131-136
- [32] Nagata K, Saga S, Yamada KM. A major collagen-binding protein of chick embryo fibroblasts is a novel heat shock protein. *The Journal of Cell Biology*. 1986;**103**:223-229
- [33] Nagata K, Saga S, Yamada KM. Characterization of a novel transformation-sensitive heat-shock protein (HSP47) that binds to collagen. *Biochemical and Biophysical Research Communications*. 1988;**153**:428-434
- [34] Nagai N, Yorihuri T, Hosokawa N, Nagata K. Human genome has a functional hsp47 gene (CBP2) and pseudogene (pshsp47). *Gene*. 1999;**227**(2):241-248
- [35] Marutani T, Yamamoto A, Nagai N, Kubota H, Nagata K. Accumulation of type IV collagen in dilated ER leads to apoptosis in Hsp47-knockout mouse embryos via induction of CHOP. *Journal of Cell Science*. 2004;**117**(Pt 24):5913-5922
- [36] Tsujimura K, Morishita M, Kawahara K, Fukunaga M, Tsuruda K, Iwamoto Y. A study on the expression of heat shock protein genes in the human periodontal ligament fibroblasts. *Journal of the Japanese Society of Periodontology*. 1995;**37**(2):287-293
- [37] Yamashita S, Maeshima A, Nojima Y. Involvement of renal progenitor tubular cells in epithelial-mesenchymal transition in fibrotic rat kidneys. *Journal of the American Society of Nephrology*. 2005;**16**:2044-2051